



**Australian Government**  

---

**Medical Services Advisory Committee**

## **Public Summary Document**

### ***Application No. 1467 – Obstetric MRI***

**Applicant:** The Royal Australian and New Zealand College of Radiologists (RANZCR)

**Date of MSAC consideration:** MSAC 72<sup>nd</sup> Meeting, 28-29 March 2018

Context for decision: MSAC makes its advice in accordance with its Terms of Reference, [visit the MSAC website](#)

#### **1. Purpose of application**

An application requesting Medicare Benefits Schedule (MBS) listing of magnetic resonance imaging (MRI) of the abdomen/pelvis of pregnant women was received from RANZCR by the Department of Health.

#### **2. MSAC's advice to the Minister**

After considering the strength of the available evidence in relation to comparative safety, clinical effectiveness and cost effectiveness, MSAC supported MBS funding of obstetric MRI of women at  $\geq 18$  weeks' gestation in whom a fetal central nervous system (CNS) abnormality is suspected and diagnosis is indeterminate on tertiary ultrasound. MSAC considered there was weak but acceptable evidence of incremental benefit over tertiary ultrasound to inform clinical decision making for CNS anomalies only.

MSAC advised that the MBS item should be confined to CNS anomalies only, but allow multiple examinations per pregnancy (noting that repeat scanning was likely to be a rare event), with an MBS fee of \$1200 (based on current MBS MRI item fees which involve two hours of radiologist time). MSAC considered that it is appropriate for providers to engage in RANZCR's relevant professional development activities as the intervention is highly specialised.

MSAC did not support public funding of obstetric MRI of women at  $\geq 28$  weeks' gestation in whom placental adherence disorder (PAD) is suspected but diagnosis is indeterminate on tertiary ultrasound, or in whom PAD is diagnosed on tertiary ultrasound and MRI is required for surgical planning of either hysterectomy or uterine conservation. MSAC advised there was insufficient evidence of:

- the diagnostic superiority of MRI over tertiary ultrasound; and
- the role of MRI in changing or determining patient management.

MSAC advised that any resubmission would need to be considered by ESC.

### 3. Summary of consideration and rationale for MSAC's advice

MSAC noted that this was a new application for listing on the MBS of MRI of the abdomen/pelvis for the management of:

- pregnant women at  $\geq 18$  weeks gestation with suspected fetal abnormality (fetal MRI); and
- pregnant women at  $\geq 28$  weeks gestation with suspected placental adhesion disorder (PAD; placental MRI).

MSAC noted that the comparator for both fetal MRI and placental MRI is tertiary obstetric ultrasound.

MSAC noted that no relevant studies were cited in the application to support evidence for comparative safety of the intervention. However, MSAC noted that both the intervention and the comparator (tertiary ultrasound) are considered safe for use in pregnancy for both fetal and maternal health (Krishnamurthy U et al 2015; Patenaude YG et al 2014; RANZCR 2017 MRI Safety Guidelines).

MSAC noted that an abridged linked evidence approach had been adopted in which studies reporting diagnostic performance of fetal MRI compared with tertiary ultrasound were included only if the impact of diagnosis on patient management or clinical decision making was also reported.

MSAC considered that, overall, the evidence profile for pregnant women with suspected fetal abnormality suggested that fetal MRI has superior effectiveness compared to tertiary ultrasound in diagnosing CNS and urogenital abnormalities, although the quality of the evidence was very low. MSAC noted that the majority of the evidence base on the diagnostic accuracy of fetal MRI referred to CNS abnormalities (one systematic review of 13 studies: Rossi & Perfumo 2014; three additional studies: Griffiths P et al 2017, Griffiths P et al 2006, Hamisa M et al 2013). In these studies, accuracy of MRI ranged from 93% to 100% compared to between 68% and 80% for tertiary ultrasound. MSAC noted that only one study referred to abdominal and urinary tract malformations (Kajbafzadeh A et al 2008), which reported greater sensitivity of MRI versus ultrasound (96% versus 58%) but also concluded that ultrasound will be adequate in the majority of cases; and two studies referred to various anomalies (Tamsel S et al 2004; Goncalves L et al 2016), both of which found MRI did not perform better than ultrasound.

MSAC noted that very low quality evidence suggested that the improved diagnostic accuracy of fetal MRI compared to tertiary ultrasound led to a change in patient management in between 19% and 35% of cases, almost entirely for CNS abnormalities (three studies; Goncalves L et al 2016; Griffiths P et al 2017; Griffiths P et al 2006). MSAC noted that no detail of change in management was provided (e.g. termination of pregnancy or fetal surgery with any impact on fetal outcome). MSAC acknowledged that termination of pregnancy was not considered an effectiveness outcome, and that change to treatment may not be appropriate for some fetal abnormalities. MSAC noted that a prospective study conducted to inform the role of MRI within the Victorian public health sector (Victorian Policy Advisory Committee on Technology [VPACT] report, 2010; n = 269) found that 3% of cases had a change in surgical plan for the fetus due to MRI, and 10% of patients who underwent MRI had a change in site, method or timing of delivery. MSAC concluded that based on evidence of superior diagnostic accuracy and change in management, fetal MRI should be limited to the investigation of CNS abnormalities.

MSAC considered that low quality evidence from observational studies suggested that the accuracy of placental MRI in pregnant women of  $\geq 28$  weeks gestation with suspected PAD, may be superior to tertiary obstetric ultrasound in identifying the degree of placental invasion and topography of invasion, but evidence for a significant difference between MRI and ultrasound in diagnosing PAD was lacking. MSAC noted that although MRI and ultrasound had similar accuracy, it could not be determined if the combination of the two tests were superior to one test alone, given that they provide different types of information. MSAC observed that studies reporting accuracy were limited by heterogeneity and included patients at high risk of PAD as well as those with suspected PAD, limiting the applicability of the findings.

MSAC noted that given the low quality and uncertain evidence associated with potential changes in medical or surgical management attributed to diagnosis of PAD after MRI, no assessment of the impact of the change in management on maternal mortality, fetal mortality, fertility conservation, or post-operative complications could be conducted.

MSAC noted the outcomes used in the fetal MRI cost-effectiveness model were ‘cost per change in prognosis’, ‘cost per additional patient with a correct diagnosis’, and ‘cost per correct diagnosis and additional information’, based on the VPACT report. MSAC considered that although the incremental cost effectiveness ratios (ICERs) were low at \$4394, \$10,417, and \$7279, respectively, these outcomes are ‘intermediate’ and not representative of clinically meaningful outcomes (such as final pregnancy outcomes, healthy births, births with abnormality, still births, or terminated pregnancies).

MSAC considered that there was uncertainty in the economic model because:

- the accuracy of MRI, including occurrences of false positives and negatives (i.e. potential harms), had not been captured in the model, leading to an overestimation of effectiveness;
- the intervention arm of the model contained fetal MRI only, assuming that no additional ultrasound or further investigations followed the identification of a potential abnormality by tertiary ultrasound, which was unlikely in clinical practice;
- the estimates of effect were based on VPACT study data alone, which had missing data (22%) and small sample numbers for secondary outcomes in the study, affecting the translation of the findings.

However, MSAC considered it unlikely that decisions such as termination of pregnancy would be made on the basis of MRI alone.

MSAC considered that the outcome on which the cost-effectiveness model for placental MRI was based (‘cost per additional valuable information to guide surgical planning’) had little value. MSAC queried the validity of the cost-effectiveness analysis and any reliable interpretation of the ICER (valued at \$1,107) considering that:

- the ‘valuable information’ outcome was not quantifiable and likely to be heterogeneous with varying clinical endpoints of indeterminate significance;
- there was no evidence linking placental MRI to superior clinically relevant outcomes;
- neither the costs nor outcome components of the ICER were comprehensive; and
- sensitivity analyses were unlikely to produce a more meaningful or accurate estimate of cost-effectiveness.

MSAC discussed the potential sources of leakage for the item, but considered that limitation of the service to specialised centres made this unlikely and that no limits should be placed on the number of rebatable examinations per pregnancy as repeat scanning was likely to be a rare event.

MSAC noted the estimated number of services over five years (critique estimated approximately 1200 and approximately 500 for fetal MRI and placental MRI, respectively) and considered the financial impact on the MBS was likely to be low (critique estimated ~\$1.4 million and ~\$250,000 for fetal MRI and placental MRI [based on an upper limit fee of \$600], respectively). MSAC considered that the estimates of utilisation for MRI were uncertain as:

- assumptions for utilisation were based on expert opinion that may not be applicable to the general obstetric Australian population;
- the referral rate for (suspected) major anomalies may be higher than 30%;
- the referral rate may be lower than the estimated 100% uptake (estimated at 71% in the Critique); and
- estimates assumed that MRI will replace additional ultrasound.

MSAC advised that based on the weak evidence of incremental benefit above tertiary ultrasound in non-CNS abnormalities, fetal MRI should be confined to suspected cases of CNS abnormalities, with no limit on multiple scans as cases where multiple scans are required are expected to be few. MSAC noted that ‘family/past pregnancy history or genetic risk’ had been removed from the indications for the service as an indeterminate result on tertiary ultrasound is an essential pre-test requirement for all patients.

MSAC discussed the proposed fee (\$1400 to \$1500), which was similar to the fee used in the VPACT model, and comparable to MBS item 63489 (MRI-guided breast biopsy) which has a fee of \$1440. MSAC considered that as there are no good benchmarks, a fee of \$1200 was reasonable based on a notional two hours of radiologist time.

MSAC advised that changes to the item descriptor should include a requirement for pre-test tertiary ultrasound provided by a specialist obstetrician, that referral for fetal MRI should be restricted to the specialist obstetrician, and that providers of this service will need obstetric MRI credentialing to be provided by the Royal Australian and New Zealand College of Radiologists (RANZCR) once a program had been developed.

MSAC considered that if a future submission for placental MRI were to be developed, the item descriptor should specify that placenta praevia on a 20 week scan should be confirmed on a 28 week scan prior to MRI.

#### **4. Background**

MSAC has not previously considered this application.

#### **5. Prerequisites to implementation of any funding advice**

Under the Health Insurance (Diagnostic Imaging Services Table) Regulation 2016, the scan must be performed under the professional supervision of the eligible provider, including if necessary, by personal attendance on the patient.

For both populations, the studies can be performed on a 1.5T or 3.0T machine. There are 346 (169 full and 177 partial) Medicare-eligible MRI units in Australia (The Department of Health, 2016). These devices are classified as Class IIa (low-medium risk) or Class IIb (medium-high risk) devices according to the Australian Regulatory Guidelines for Medical Devices (noting that these guidelines are currently under review) (TGA, 2011).

## 6. Proposal for public funding

The proposed MBS item descriptor for MRI of the abdomen of pregnant women of  $\geq 18$  weeks' gestation with suspected fetal abnormality is summarised in Table 1.

The proposed MBS item descriptor for MRI of the abdomen of pregnant women of  $\geq 28$  weeks' gestation with suspected placental adhesion disorder of is summarised in Table 2.

**Table 1 Proposed MBS item descriptor for MRI of the abdomen of pregnant women of >18 weeks with suspected fetal abnormality**

| Category 5 - DIAGNOSTIC IMAGING SERVICES  |
|---|
| MAGNETIC RESONANCE IMAGING performed under the professional supervision of an eligible provider at an eligible location for the following indications:<br>Pregnant woman 18 weeks gestation or greater with suspected fetal abnormality based on tertiary ultrasound or family / past pregnancy history or genetic risk referred by an appropriate specialist or maternal fetal medicine specialty unit where diagnosis is indeterminate on tertiary ultrasound |
| Fee: \$1400-\$1500  |

**Table 2 Proposed MBS item descriptor for MRI of the abdomen of pregnant women of >28 weeks with suspected placental adhesion disorder**

| Category 5 - DIAGNOSTIC IMAGING SERVICES  |
|---|
| MAGNETIC RESONANCE IMAGING performed under the professional supervision of an eligible provider at an eligible location for the following indications:<br>Pregnant woman 28 weeks gestation or greater with suspected placental adhesion disorder referred by an obstetric specialist involved in treatment and pregnancy management where:<br>Diagnosis is indeterminate on tertiary ultrasound OR<br>MRI is required for surgical planning of either hysterectomy or uterine conservation interventions |
| Fee: \$500-\$600  |

The proposed items are limited to specialist referral, noting that MRI should not be available as a stand-alone screening test for fetal anomalies, and should always be offered after a tertiary US has not provided or cannot provide sufficient or complete diagnostic information.

The fee for the proposed items has been estimated based on prior experience suggesting that:

- A fetal MRI takes approximately two hours to perform. It is a complex scan requiring the direct involvement of (or consultation with) a senior radiologist for two hours and a senior radiographer for one hour.
- An MRI for placental adhesion disorder takes approximately an hour to perform (half an hour of radiologist time and half an hour of radiographer time) and is similar in complexity to MBS item 63473 (pelvic and upper abdomen MRI for staging cervical cancer) which has a fee of \$627.20.

## 7. Summary of Public Consultation Feedback/Consumer Issues

The Department received responses from two organisations. Overall, both responses were supportive of the proposed intervention. However, one of the organisations expressed concerns regarding the referral pathway for the service; and considered the proposed fees to be inappropriately high.

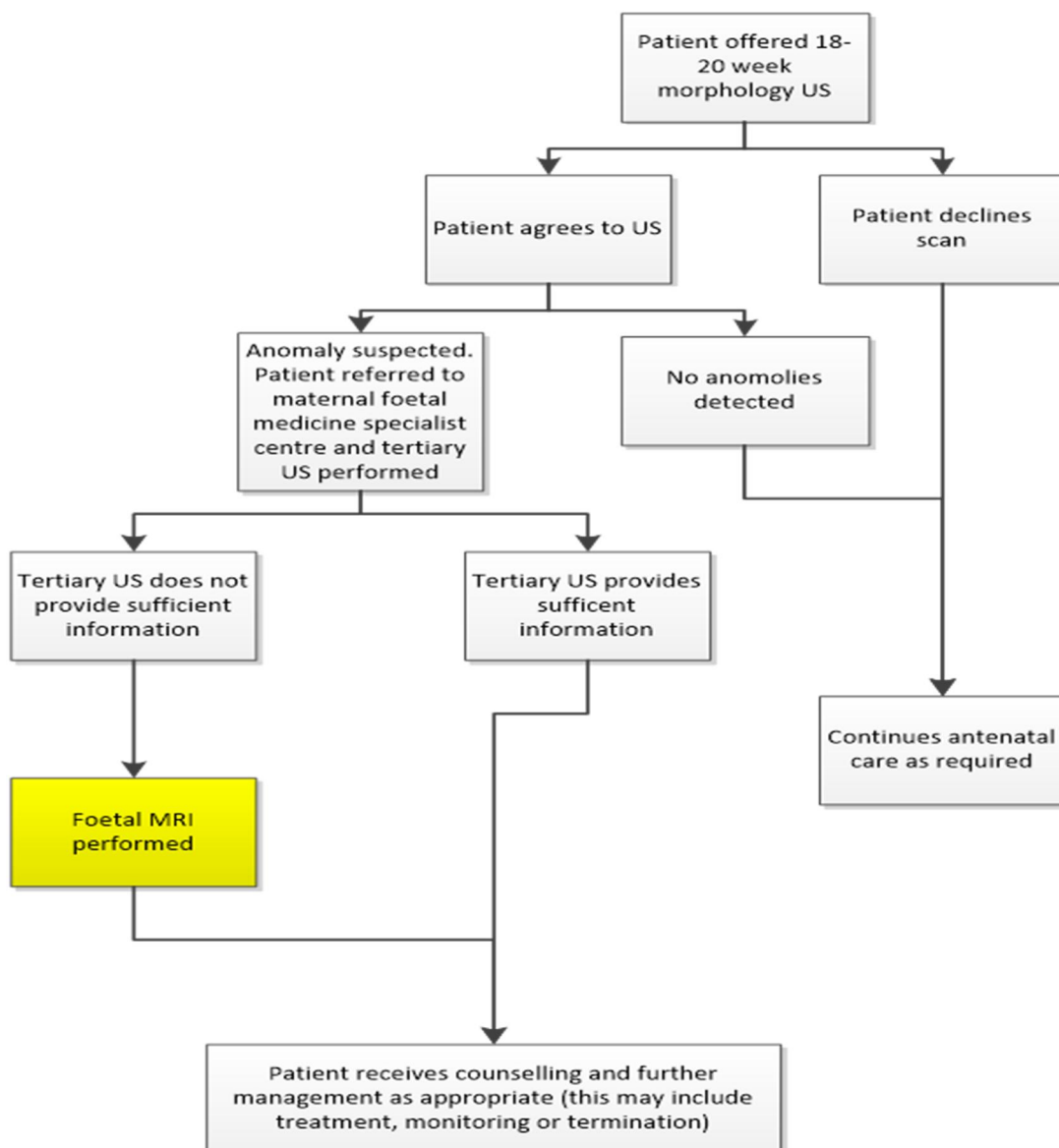
## 8. Proposed intervention's place in clinical management

### *Fetal MRI*

The proposed clinical management algorithm for fetal MRI of the abdomen of pregnant women of  $\geq 18$  weeks' gestation with suspected fetal abnormality relative to current clinical practice is presented in Figure 1.

A screening US is performed at 18-20 weeks' gestation to evaluate the fetus for structural abnormalities and to assess the position of the placenta (Australian Health Ministers' Advisory Council, 2014, RANZCOG, 2016). A suspected fetal anomaly at the screening US will prompt referral for an obstetric tertiary US. Patients with suspected fetal abnormalities may also be referred for amniocentesis and/or genetic microarray testing. In women in whom the tertiary US does not provide sufficient information, a fetal MRI would be performed.

Figure 1 Proposed clinical practice: Population 1 (fetal abnormalities)



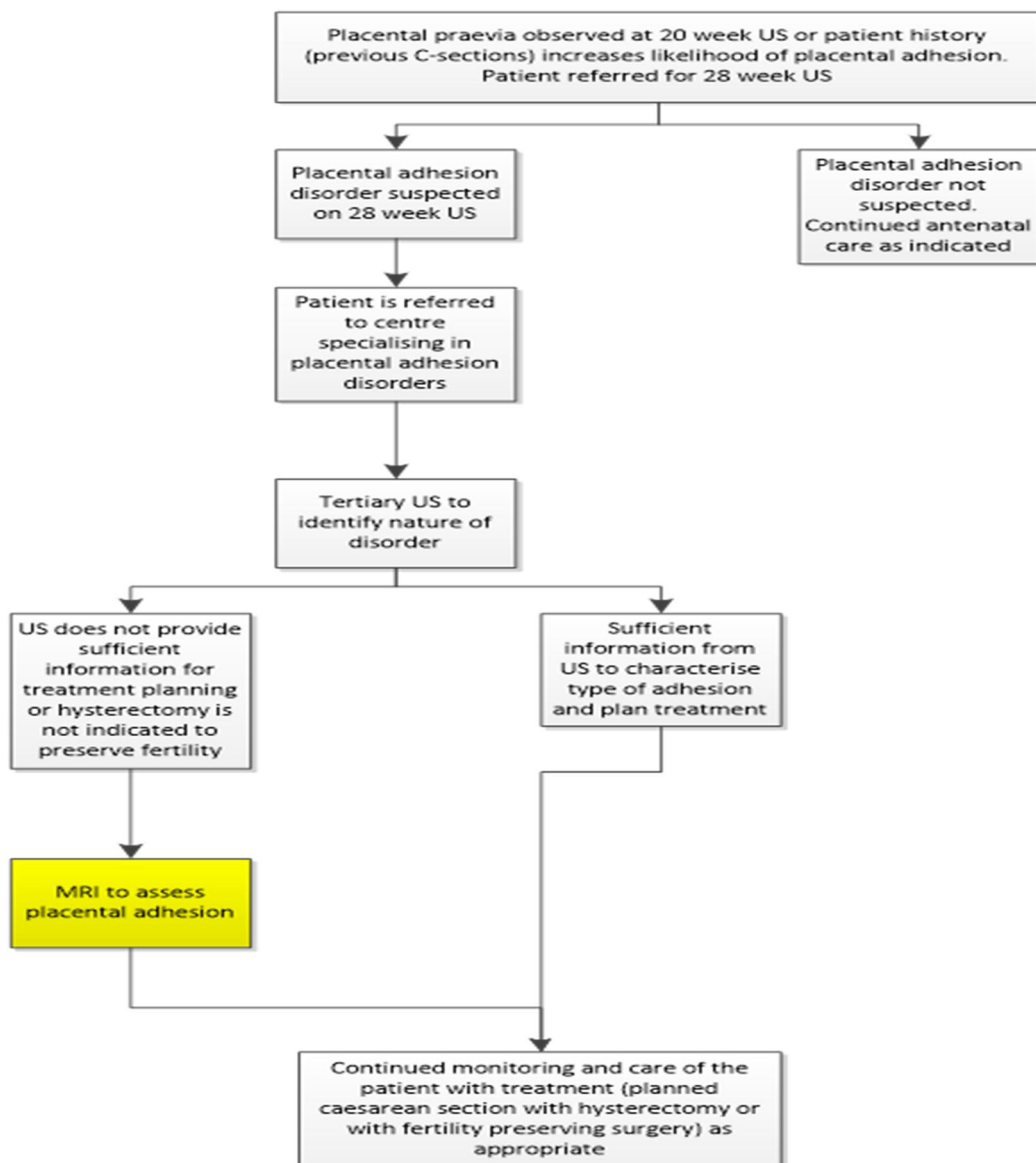
## Placental MRI

The proposed clinical management algorithm for placental MRI of the abdomen of pregnant women of  $\geq 28$  weeks' gestation with suspected PAD relative to current clinical practice is provided in Figure 2b.

Women with suspicion or at risk of PAD at the 18–20 week screening US (e.g., due to placenta praevia), would have a follow-up tertiary US at 28-weeks. In women in whom the tertiary US does not provide sufficient information, a placental MRI would be performed.

MRI is required when the tertiary obstetric US is indeterminate, unable to identify the nature of the adhesion of the placenta to the surrounding tissue or, if preservation of fertility is the desired outcome, to determine the safety or feasibility of avoidance of peripartum hysterectomy.

Figure 2 Proposed clinical practice: Population 2 (placental adhesion disorder)



## **9. Comparator**

For both populations, the comparator is a tertiary obstetric US (also a required prior test). MRI is only indicated when the tertiary US does not provide sufficient information to diagnose the condition and/or counsel the patient on treatment options.

For the linked evidence approach, the most appropriate reference standard for diagnosis of fetal abnormalities or for confirmation of PAD was determined to be final diagnosis after clinical follow-up. This may include a composite of several test results performed at delivery, postnatal, or at post-mortem, to produce a better indicator of true disease status.

## **10. Comparative safety**

No studies were identified that could inform on the safety of fetal MRI, placental MRI or US as they are all considered safe for use in pregnancy for both maternal and fetal health.

## **11. Comparative effectiveness**

### *Fetal MRI*

One systematic review (Rossi and Prefumo, 2014) of thirteen studies and six additional studies (Griffiths et al., 2017, Griffiths et al., 2006, Hamisa et al., 2013, Kajbafzadeh et al., 2008, Tamsel et al., 2004, Goncalves et al., 2016) were identified that reported both diagnostic accuracy of fetal MRI compared with US and the associated change in patient management.

Few studies provided clear inclusion/exclusion criteria, enrolled consecutive patients, or provided sufficient information as to why the MRI was offered. Description of the prior US, and timing between US and MRI was often not provided. In addition, the radiologists interpreting the MRI scans were not blinded to the results of US and clinical assessments, which could result in overoptimistic estimates of the diagnostic accuracy of MRI.

### *Accuracy*

Moderate quality evidence suggested that the diagnostic sensitivity of fetal MRI in pregnant women of  $\geq 18$  weeks' gestation with suspected fetal abnormality is superior to tertiary obstetric ultrasound for the diagnosis of fetal abnormalities. Evidence for the specificity of MRI in ruling out various fetal abnormalities compared with US was less certain as it is not possible to accurately estimate true negatives and false negative in the sample population. This is an inevitable consequence of abnormal US being a required prior test, with specificity data for US provided in only three studies. The reported sensitivity of MRI ranged between 74% and 99% and specificity ranged between 70% and 100%. Where available, reported sensitivity of tertiary US ranged between 30% and 100%, with specificity ranging between 92% to 100%.

Significant heterogeneity was detected among the included studies. MRI appeared to be more sensitive in detecting fetal CNS abnormalities and fetal urogenital abnormalities than abnormalities in other fetal organ systems. Two studies noted that adding MRI to the diagnostic pathway led to an increase of 20% to 25% in the accuracy of detecting CNS abnormalities.



### *Therapeutic efficacy (change in management)*

Overall, there is very low quality evidence available to show the impact of fetal MRI on the clinical management of pregnant women with suspected fetal abnormalities compared with US.

Data from eight studies involving 1061 participants suggested that MRI provided additional findings that led to change in management in 19% to 35% of cases. Three studies involving 767 patients reported that patient counselling was altered in 10% to 15% of cases. MRI also impacted the diagnosis in 61% of cases, changed prognosis in 44% of patients, and increased the confidence of clinicians in diagnosing or excluding fetal CNS anomalies in 13% of cases. One study involving 157 patients suggested clinicians reported a similar level of confidence in MRI for diagnosis of congenital abnormalities and lower level of confidence in excluding subtle brain abnormalities as compared to US. None of the included studies that reported the proportion of patients with a change in management, diagnosis or prognosis as a result of the fetal MRI assessed this outcome against a reference standard (i.e. the accuracy of the change in management was not assessed).

In its pre-MSAC response the applicant noted that due to the review methodology, which only included diagnostic accuracy studies if they also assessed the effect of fetal MRI on management or treatment, over 90% of studies that evaluated the diagnostic accuracy of fetal MRI were excluded.

### ***Placental MRI***

The evidence relating to diagnostic performance comparing placental MRI with US in the diagnosis of a PAD was based on six prospective cohort studies (Algebally et al., 2014, Elhawary et al., 2013, Maher et al., 2013, Mansour and Elkhyat, 2011, Peker et al., 2013, Rezk and Shawky, 2016) and four retrospective cohort studies (Aitken et al., 2016, Lin et al., 2017, Moodley et al., 2004, Palacios-Jaraquemada et al., 2013). Surgical findings (or in combination with pathology results) were nominated as the reference standard in all studies.

### *Accuracy*

Low quality evidence suggested that the accuracy of placental MRI in pregnant women of  $\geq 28$  weeks' gestation with suspected PAD, may be superior to tertiary obstetric ultrasound in identifying the degree of placental invasion and topography of invasion, but evidence for a significant difference between MRI and US in diagnosing PAD was lacking. The reported sensitivity of MRI ranged between 60% and 100% and specificity ranged between 76% and 100%. Reported sensitivity of tertiary US ranged between 60% and 100%, with specificity ranging between 80% to 100%. The data were limited by heterogeneity and applicability to the MSAC population, with most identified studies enrolling pregnant women with suspected PAD. The small number of samples or patients with indeterminate US may restrict the evaluation of the MRI results.

### *Therapeutic efficacy (change in management)*

Very low quality evidence was available to assess the impact of placental MRI on the clinical management of pregnant women with suspected PAD compared with prior US. The evidence is inconclusive as to whether any additional topographic information provided by MRI may impact on the clinical management of pregnant women of  $\geq 28$  weeks' gestation with suspected PAD compared with US. Given that placental MRI could accurately characterise the level and topography of invasion compared with US, this new information could be used to inform different surgical planning options, such as hysterectomy or conservative reconstructive procedures. However, there are no properly designed comparative studies to demonstrate the translation of the additional MRI information into the net change in clinical

management. This is further confirmed by a study which failed to demonstrate that the accuracy of MRI is sufficient to impact on mode of delivery.

### ***Clinical Claim***

It is claimed that fetal MRI and placental MRI have non-inferior safety compared to tertiary US. For both populations, MRI is claimed to provide superior diagnostic capabilities than the comparator for certain fetal abnormalities/conditions and for placental adhesion disorders that cannot be adequately characterised or diagnosed with ultrasound, particularly when the placenta is posterior or when there are multiple fetuses. Accurate antenatal diagnosis of invasive placentation allows for better patient counselling and delivery planning, including ensuring availability of blood products and mobilisation of a multidisciplinary team if required.

After diagnosis of a fetal abnormality the family would be counselled on the details of the abnormality and on the prognosis and possible implications to the fetus, patient, and future pregnancies (McLennan and Walker, 2016). Based on this counselling, a decision would be made that may involve continuation of the pregnancy with specialist support, neonatal palliation in the case of a non-treatable abnormality, or termination of the pregnancy. Where indicated, advice would be provided regarding the role of genetic testing and the risk of recurrence of the fetal abnormality in future pregnancies.

The main strategy for managing women with PAD is elective caesarean hysterectomy. Other procedures such as preoperative ureteric stent placement and intraoperative internal iliac balloon inflation may also be required to significantly reduce maternal blood loss, morbidity, and mortality (Aitken et al., 2016). A more conservative approach would be to attempt to preserve fertility, by leaving the placenta *in situ* (after caesarean section) and encourage spontaneous shedding of the placenta, sometimes with the use uterine artery embolization. Confirmed absence of PAD after MRI would potentially avoid unnecessary peripartum hysterectomy.

## **12. Economic evaluation**

A summary of the key characteristics of the economic evaluation is shown in Table 3.

**Table 3 Summary of the economic evaluation**

|   |  |  |
|---|--|--|
| <b>Population</b>                       | Pregnant women >18 weeks gestation with suspected fetal abnormality based on tertiary US | Pregnant women >28 weeks gestation with suspected placental adhesion referred by an obstetric specialist |
| <b>Perspective</b>                      | Australian government  | Australian government  |
| <b>Comparator</b>                       | US   | US   |
| <b>Type of economic evaluation</b>      | Cost-effectiveness   | Cost-effectiveness   |
| <b>Sources of evidence</b>              | VPACT report + supportive evidence   | Aitken 2016 + supportive evidence  |
| <b>Outcomes</b>                         | Patients with correct change in diagnosis  | Additional valuable information to guide surgical decision making  |
| <b>Methods used to generate results</b> | Decision tree analysis   | Decision tree analysis   |
| <b>Software packages used</b>           | TreeAge Pro 2017 R2.0®, MS Excel 2016®   | TreeAge Pro 2017 R2.0®, MS Excel 2016®   |

For fetal MRI, costs and outcomes using the VPACT report results and updated cost information are presented in Table 4.

**Table 4 Fetal MRI incremental cost-effectiveness ratios**

|  | Cost    | Incremental cost | Effectiveness | Incremental effectiveness | ICER     |
|--|---------|------------------|---------------|---------------------------|----------|
| <b>Cost per change in prognosis</b>                          |         |                  |               |                           |          |
| Intervention   | \$1,450 | \$1,450          | 33.00%        | 33.00%                    | \$4,394  |
| Comparator   | \$0     |                  | 0             |                           |          |
| <b>Cost per correct diagnosis</b>                            |         |                  |               |                           |          |
| Intervention   | \$1,450 | \$1,450          | 13.92%        | 13.92%                    | \$10,417 |
| Comparator   | \$0     |                  | 0             |                           |          |
| <b>Cost per correct diagnosis and additional information</b> |         |                  |               |                           |          |
| Intervention   | \$1,450 | \$1,450          | 19.92%        | 19.92%                    | \$7,279  |
| Comparator   | \$0     |                  | 0             |                           |          |

ICER = Incremental Cost Effectiveness Ratio;

The results reported for fetal MRI show an ICER between \$1,167 and \$10,417 when applying a lower cost associated with MRI, costs per correct change in diagnosis, cost per increased accuracy for CNS and cost per change in management.

In the pre-MSAC response the applicant noted that the calculated ICER for fetal MRI is likely to be overestimated due to limitations with the assumptions in the cost-effectiveness estimates.

For placental MRI, outcomes from Aitken 2016 are used to estimate a cost per additional valuable information to guide surgical planning, shown in Table 5.

**Table 5 Placental MRI cost per additional information**

|              | Cost  | Incremental cost | Effectiveness (valuable information) | Incremental effectiveness | ICER    |
|--------------|-------|------------------|--------------------------------------|---------------------------|---------|
| Intervention | \$550 | \$465            | 83.90%                               | 42.00%                    | \$1,107 |
| Comparator   | \$85  |                  | 41.90%                               |                           |         |

Sensitivity analyses were performed adjusting the cost of MRI and considering other metrics including increased accuracy, change in management following MRI, change in diagnosis and change in level of invasion.

In placental MRI the cost per additional information is reasonably sensitive to the cost per change in severity of diagnosis and invasion level. However, in all scenarios, the ICER is less than \$2,000.

There is a high degree of uncertainty surrounding the results due to; 1) the low level evidence used to inform the EE; 2) the plausibility of ‘additional information’ as a clinical meaningful outcome and; 3) structural issues in the EE that do not consider that diagnosis may be less accurate after the MRI (as per the VPACT report).

### 13. Financial/budgetary impacts

The estimated financial costs associated with the introduction of MRI for these populations have been determined using an epidemiological approach.

The financial implications to the MBS resulting from the proposed listing of obstetric MRI for fetal abnormalities and placental adhesion are summarised in Table 6.

The cost to the MBS for obstetric MRI is estimated in the application to be approximately \$1.1-\$1.2 million per year.

**Table 6 Total projected costs to the MBS associated with obstetric MRI**

| Population              | 2018        | 2019        | 2020        | 2021        | 2022        |
|-------------------------|-------------|-------------|-------------|-------------|-------------|
| <b>Fetal MRI</b>        |             |             |             |             |             |
| Number of patients      | 735         | 747         | 759         | 771         | 783         |
| Total cost              | \$1,065,484 | \$1,083,181 | \$1,100,830 | \$1,118,367 | \$1,135,873 |
| MBS rebate (85%)        | \$905,661   | \$920,704   | \$935,706   | \$950,612   | \$965,492   |
| Patient contributions   | \$159,823   | \$162,477   | \$165,125   | \$167,755   | \$170,381   |
| <b>Placental MRI</b>    |             |             |             |             |             |
| Number of patients      | 482         | 490         | 498         | 506         | 514         |
| Total cost              | \$265,204   | \$269,608   | \$274,002   | \$278,367   | \$282,724   |
| MBS rebate (85%)        | \$225,423   | \$229,167   | \$232,901   | \$236,612   | \$240,315   |
| Patient contributions   | \$39,781    | \$40,441    | \$41,100    | \$41,755    | \$42,409    |
| <b>Total population</b> |             |             |             |             |             |
| Total cost              | \$1,330,687 | \$1,352,789 | \$1,374,832 | \$1,396,734 | \$1,418,597 |
| MBS rebate (85%)        | \$1,131,084 | \$1,149,871 | \$1,168,607 | \$1,187,224 | \$1,205,808 |
| Patient contributions   | \$199,603   | \$202,918   | \$206,225   | \$209,510   | \$212,790   |

MBS = Medicare benefits schedule

The Critique advised that the CA appeared to have advised whether there are safety net implications, and the calculations appear to assume that there are none.

This may not be accurate given that intensive pregnancy monitoring may mean that many women reach safety net limits during obstetric care.

The Critique also advised that there may be potential for the net cost/year to the MBS to be greater than estimated in the CA, given:

- The estimates of referral and uptake are uncertain, but are likely underestimates (revised and increased estimates for numbers of fetal MRI are presented in Table 7 below)
- Services assumed to be substituted – i.e. fetal US, may in fact still occur
- The market may increase and the proposed restriction may be interpreted more broadly than expected.

The cost to the MBS for obstetric MRI is estimated in the critique to be approximately \$1.6 - \$1.7 million per year.

**Table 7 Total costs to the MBS associated with obstetric MRI (fetal and placental)**

|  | 2018               | 2019               | 2020               | 2021               | 2022               |
|--|--------------------|--------------------|--------------------|--------------------|--------------------|
| <b>Fetal MRI</b>                         |                    |                    |                    |                    |                    |
| Number of services                       | 735                | 747                | 759                | 771                | 783                |
| Sub-total cost (benefits)                | \$905,661          | \$920,704          | \$935,706          | \$950,612          | \$965,492          |
| <i>Number of services (amended)</i>      | <i>1181</i>        | <i>1201</i>        | <i>1221</i>        | <i>1241</i>        | <i>1261</i>        |
| <i>Sub-total cost (benefits) amended</i> | <i>\$1,355,198</i> | <i>\$1,378,148</i> | <i>\$1,401,098</i> | <i>\$1,424,048</i> | <i>\$1,446,998</i> |
| <b>Placental MRI</b>                     |                    |                    |                    |                    |                    |
| Number of services                       | 482                | 490                | 498                | 506                | 514                |
| Sub-total cost (benefits)                | \$184,437          | \$187,500          | \$190,556          | \$193,591          | \$196,622          |
| <i>Sub-total cost (benefits) amended</i> | <i>\$225,423</i>   | <i>\$229,167</i>   | <i>\$232,901</i>   | <i>\$236,612</i>   | <i>\$240,315</i>   |
| <b>Total obstetric MRI</b>               |                    |                    |                    |                    |                    |
| Number of services                       | 1217               | 1237               | 1257               | 1277               | 1297               |
| Total cost (benefits)                    | \$1,090,098        | \$1,108,204        | \$1,126,262        | \$1,144,204        | \$1,162,114        |
| <i>Number of services (amended)</i>      | <i>1663</i>        | <i>1691</i>        | <i>1719</i>        | <i>1747</i>        | <i>1775</i>        |
| <i>Total cost (benefits) amended</i>     | <i>\$1,580,621</i> | <i>\$1,607,315</i> | <i>\$1,633,999</i> | <i>\$1,660,660</i> | <i>\$1,687,313</i> |

#### 14. Key issues from ESC for MSAC

This submission is a new application to support the listing on the Medicare Benefits Schedule (MBS) of magnetic resonance imaging (MRI) of the abdomen/pelvis to be offered as an additional test following an inconclusive tertiary ultrasound (US) for two populations:

- pregnant women of 18 or more weeks' gestation with suspected fetal abnormality (population 1, fetal MRI); and
- pregnant women of 28 or more weeks' gestation with suspected placental adhesion disorder (PAD; population 2, placental MRI).

The claim is that the successful listing of the technology in the target population and setting will allow more accurate diagnosis of fetal abnormalities and PADs ultimately leading to more accurate surgical and medical pregnancy management or better prognostic, genetic and family counselling; and, in the case of suspected PAD, a potential reduction in fetal and maternal mortality and a greater likelihood of preservation of fertility (through avoidance of hysterectomy).

ESC noted that both the intervention and the comparator (US) are considered safe for use in pregnancy for both fetal and maternal health (that is, non-contrast MRI has non-inferior safety versus US).

With regards to *population 1*, ESC noted that no evidence from comparative trials was available to address the effectiveness of fetal MRI and subsequent clinical management on patient prognosis, quality of care, or confidence in decision making compared to tertiary US.

ESC noted that in the absence of high quality evidence, an abridged linked evidence approach had been adopted in which studies reporting diagnostic performance of fetal MRI compared with US were included only if the impact of diagnosis on patient management or clinical decision making were also reported.

ESC noted that the evidence profile for pregnant women  $\geq 18$  weeks gestation with suspected fetal abnormality suggests fetal MRI has superior effectiveness compared to US in diagnosing fetal abnormalities, although the quality of the evidence was very low.

ESC noted that the majority of the evidence base on the diagnostic accuracy of fetal MRI referred to central nervous system (CNS) abnormalities (one systematic review of 13 studies: Rossi & Perfumo 2014; 3 additional studies: Griffiths P et al 2017, Griffiths P et al 2006, Hamisa M et al 2013). In these studies, accuracy of MRI ranged from 93% to 100% compared to between 68% and 80% for US.

One study referred to abdominal and urinary tract malformations (Kajbafzadeh A et al 2008), reporting greater sensitivity of MRI versus US (96% versus 58%); and two studies referred to various anomalies (Tamsel S et al 2004; Goncalves L et al 2016), the majority of which were CNS abnormalities, in which MRI did not perform better than US.

ESC noted that very low quality evidence suggests that the improved diagnostic accuracy of fetal MRI compared to tertiary US led to a change in patient management in between 19% and 35% of patients. ESC noted that included studies ostensibly addressing change in clinical management reported diagnostic confidence and change in patient counselling, with one study (Griffiths P et al 2017) reporting change in management as being either 'significant', 'decisive' or of 'major influence'. However, ESC noted that no detail of actual change management was provided (e.g. termination of pregnancy or fetal surgery with any impact on fetal outcome),

ESC noted that the evidence for fetal MRI included information from a prospective study with a pre and post observational design conducted to inform the role of MRI within the Victorian public health sector (Victorian Policy Advisory Committee on Technology [VPACT] report, 2010; N = 269). The primary clinical outcome reported by VPACT was ‘change in prognosis for the fetus’; this report found that 3% of cases had a change in surgical plan for the fetus due to MRI, and 10% of patients who underwent MRI had a change in site or method or timing of delivery.

With regards to *population 2*, ESC considered that there is currently no good evidence of diagnostic superiority for placental MRI over tertiary US in detecting PAD. ESC considered that MRI may be superior to US in diagnosing the degree and topography of placental invasion, however evidence suggesting changes in medical or surgical management attributed to diagnosis of PAD after MRI compared with US was inconclusive, therefore the clinical impact of a change in management on patient outcomes was not assessed.

ESC noted that the evidence for diagnostic accuracy of placental MRI consisted of four retrospective studies which included patients who had indeterminate tertiary US, but also patients who (having signs of abnormal placentation) based on US or MRI), were identified as being at high risk of PAD (. ESC noted that the population for whom MBS listing is sought is women with a ‘suspected placental adhesion disorder referred by an obstetric specialist’, thus the proposed population may be broader than that in the evidence base and include more cases where a suspected PAD is subsequently not found to be present.

With regards to *population 1*, ESC noted that for cost-effectiveness, model inputs were based on the VPACT study. ESC noted that although the primary clinical outcome reported in the VPACT study was ‘change in prognosis for the fetus’, the outcomes used in the model were ‘cost per change in prognosis’, ‘cost per additional patient with a correct diagnosis’, and ‘cost per correct diagnosis and additional information’. The incremental cost effectiveness ratios (ICERs) were \$4,394, \$10,417, and \$7,279, respectively. ESC noted that these are ‘intermediate’ outcomes and do not represent clinically meaningful outcomes such as final pregnancy outcome, healthy births, births with abnormality, still births, or terminated pregnancies; hence, interpretation of the ICERs is difficult.

ESC also noted that the translation of findings into a quantitative assessment of cost-effectiveness is of limited usefulness due to uncertainty given that the VPACT study was missing 22% of the data and had small sample sizes for some sub-groups and secondary outcomes.

ESC noted that there were technical concerns with the fetal MRI model structure. The cost-effectiveness decision methodology in the report described 1) change from an inaccurate US-based diagnosis to an accurate MRI-based diagnosis, and 2) change from an accurate US-based diagnosis to an inaccurate MRI-based diagnosis, in addition to pathways where there is no change to the diagnosis following MRI. ESC noted, however, that the ICER calculations presented did not include the equivalent cost offsets for the second group of incorrect changes (i.e. change from a correct diagnosis to an incorrect diagnosis following MRI), resulting in the effectiveness of the intervention being overstated.

ESC noted that the cost-effectiveness analysis for placental MRI (*population 2*) was based on a direct but non-randomised trial (Aitken K et al 2016), the findings of which presented insufficient evidence to suggest that the addition of MRI to US would result in more cases of PAD being identified. Consequently, the model adopted ‘cost per additional valuable information to guide surgical planning’ as the main outcome measure. ESC noted that based on this outcome, the model generated an ICER of \$1107.

ESC noted the difficulty in any reliable interpretation of this ICER, as the ‘valuable information’ outcome is likely to be heterogeneous with respect to the significance of associated clinical endpoints, and there is currently no objective method to quantify the clinical value of ‘the valuable information’.

ESC noted that assumptions for utilisation of placental MRI in conjunction with tertiary US in the economic modelling were based on expert opinion that may not be applicable to the general obstetric Australian population, and suggested that further commentary and data were required to substantiate such claims.

ESC noted that the estimates of utilisation for fetal MRI (30% of suspected malformations; 465 to 930 per annum) may have been underestimated as:

- the referral rate for (suspected) major anomalies may be higher than 30%;
- some cardiac anomalies are likely to be referred to fetal MRI (Wielandner A et al 2013);
- MRIs undertaken in suspected cases that do not turn out to have an anomaly (i.e. true negatives), have not been accounted for. In the case of the VPACT data on fetal MRI use, 39% of patients receiving MRI had a prognosis of ‘normal’.

ESC noted that the estimate of the number of services associated with obstetric MRI is the same as the number of eligible patients, and explicitly assumes that obstetric MRI is performed only once per patient. However, ESC noted that for fetal MRI, 20% of patients would require a second scan to monitor a progressing or regressing situation, and up to 10% of patients would require three or more scans. In addition up to 10% of patients with PAD would require more than one MRI scan during pregnancy.

ESC noted that following a revision of financial estimates to include subsequent MRIs, there was an increase to the five year estimated budget from \$1.4 million to \$1.8 million.

ESC noted that the item descriptor for fetal MRI excludes pregnancies with ‘diagnosed’ or ‘definite’ fetal abnormalities and does not include women in whom further information on *prognosis* is desired.

ESC noted several potential sources of leakage that may arise due to the current wording of the item descriptors:

- although the intervention is highly specialised, the descriptor does not specify either the level of qualification or training required for the ‘eligible provider’ and MRI radiographer performing the service (populations 1 and 2);
- the descriptor does not specify the number of rebatable examinations per pregnancy (populations 1 and 2); and
- the terms ‘suspected’ and ‘indeterminate’ may be interpreted subjectively, leading to increased patient demand and increased ‘defensive medical practice’, although the limitation of the service to specialised centres made this less likely (population 1).

ESC noted the Department’s recommendation that the descriptor for fetal MRI should specify the requester as for MBS Item 55712 (US of pelvis or abdomen for pregnancy related or pregnancy complication, fetal development and anatomy).

ESC discussed whether fetal abnormalities that cannot be diagnosed on US should be specified in the item descriptor and request form. ESC considered that this amendment to the item descriptor or noted on the referral is not appropriate due to the potential for unwarranted concern to patients, and the small population.

ESC recommended that the item descriptor for placental MRI be amended to require that the requester specifies on the request form that PAD is indeterminate on tertiary US. However, ESC noted that discussions with the applicant regarding modifications to the descriptor indicated a reluctance to deviate from the specified protocol.

ESC additionally noted that placenta praevia identified on a 20-week scan should be confirmed on a 28-week scan before proceeding to tertiary US with or without MRI to prevent inappropriate referral.

ESC noted the claim by the applicant that fetal MRI takes up to two hours to perform, is a complex scan requiring the direct involvement/consultation of a senior radiologist across the two hours, and a senior radiographer for one hour, and the time involved in reporting is not comparable with existing items. ESC noted that due to the complexity of obstetric MRI, the applicant's proposed fee (~\$1500) was the equivalent of:

- MBS item 63473 – MRI scan of the pelvis and upper abdomen, in a single examination, for the staging of histologically diagnosed cervical cancer (fee \$627.20); plus
- MBS item 63052 – MRI scan of the head for congenital malformation of the brain or meninges (fee \$403.20); plus
- MBS item 63385 – MRI scan of the cardiovascular system for congenital disease of the heart or a great vessel (fee \$448).

ESC noted that the Royal Australian and New Zealand College of Obstetricians and Gynaecologists (RANZCOG) had provided consultation feedback that the proposed fee of ~\$1400 to \$1500 for fetal MRI was inappropriately high and recommended that the fee align with existing MRI MBS item fees.

ESC noted that the MBS fee of \$690 for breast MRI (MBS item 63487) allows for one hour of radiologist and radiographer time (for approximately 30 minutes each); the addition of \$600 to reach the total of three hours of specialist time required for the fetal MRI would result in a total fee of \$1290. This fee is comparable to MBS item 63489 (MRI-guided breast biopsy), which has an MBS fee of \$1440 including \$450 of consumable equipment cost and two hours of radiologist time. The fee for fetal MRI would include \$990 and \$300 for one additional hour of radiographer time, for a total of \$1290.

ESC noted that the applicant's proposed MBS fee for listing of suspected PAD is between \$500 and \$600, with the scan taking approximately one hour to perform (half an hour of radiologist time and half an hour of radiographer time). ESC noted that the complexity of placental MRI is equivalent to MBS item 63470 (MRI of the pelvis for the staging of cervical cancer; fee \$403.20) or MBS item 63473 (MRI of the pelvis and upper abdomen, in a single examination, for the staging of histologically diagnosed cervical cancer; fee \$627.20) as proposed by the applicant.

ESC also suggested that a range of fees should be used in the sensitivity analyses.

ESC noted that fetal MRI is highly specialised and is currently almost exclusively performed in eight existing specialist metropolitan centres in Australia, mainly in public hospitals. ESC noted that there will be potentially a 100% cost shift from the public to private sector for fetal MRI as most patients will be deemed outpatients.

ESC noted that there will also be potentially a 100% cost shift from the public to private sector for placental MRI. ESC noted that placental MRI is less complex than fetal MRI and



can be performed in a wider range of centres. ESC noted that the matter of the qualifications of eligible providers for placental MRI is important as evidence showed consistently higher interobserver agreements were reported for senior compared with junior radiologists, and more MRI features achieved better interobserver agreements among senior radiologists.

ESC noted that the Department and the RANZCR consider that credentialling / training would be required to ensure quality reporting of obstetric MRI.

ESC noted that the Department will consult with the Australian Society of Medical Imaging and Radiation Therapy (ASMIRT) to ascertain if an obstetric MRI credentialling program for radiographers is available.

ESC noted the potential to disadvantage to some patients due to high out-of-pocket costs and the need to travel to specialist centres to access the service. However, it was noted that tertiary US services are more widely available in the community sector and are not limited to specialist centres, and a subspecialty of obstetric US already exists. ESC noted that in cases where time delay was a factor, private clinics worked with public services to meet this need.

| ESC Key ISSUES                                  | ESC ADVICE   |
|---|--|
| <b>Training and credentialling of providers</b> | Department and the RANZCR consider that credentialling / training would be required to ensure quality reporting of obstetric MRI   |
| <b>Descriptor issue</b>                         | Fetal MRI: <ul style="list-style-type: none"> <li>• define ‘suspected’, ‘indeterminate’</li> <li>• Frequency per pregnancy</li> </ul>  |
| <b>Justification of fees</b>                    | Noted the requested fees and other similar MRI items. A range of fees should be used in the sensitivity analyses   |
| <b>Placental MRI</b>                            | No good evidence of diagnostic superiority over tertiary US<br>No evidence of change in management or improved outcome   |
| <b>Model assumptions</b>                        | Structure and effectiveness assumptions of model that will likely underestimate ICER (although ICER is in low range (\$4,000/\$10,000). Long term outcomes that cannot be modelled likely to favour intervention.                        |
| <b>CEA</b>                                      | Query if the CEA is appropriate given no superior benefit found for placental MRI. Whether the suggested effectiveness of valuable information is plausible and indicative of clinical benefit sufficient to accept the calculated ICER. |
| <b>Utilisation underestimated</b>               | Revised cost to government of 1.4-1.6M/year (7.2-8.2 M over 5 years)   |

## 15. Other significant factors

Nil

## 16. Applicant's comments on MSAC's Public Summary Document

The Applicant has indicated, throughout the process of literature review and development of review methodology, that the logic of concluding that non-CNS applications of MRI for suspected fetal abnormality have unproven diagnostic accuracy is flawed. This is due to the abridged linked evidence approach which excluded studies that did not directly address **both** diagnostic accuracy and one or more aspects of effectiveness (e.g. change to prognosis, change to treatment). If studies relating to, for example, congenital diaphragmatic hernia, assessment of fetal airway obstruction in the fetus with a neck mass or severe micrognathia, megacystis, urogenital malformation, bowel obstruction, abdominal and chest masses did not address an aspect of effectiveness, they were excluded. Once excluded, it is neither logical nor correct to then state there is no evidence to support the added *diagnostic benefit / accuracy* of fetal MR for these indications. But this is the reasoning that has been used to justify exclusion of non-CNS applications of fetal MR from the ESC recommendation regarding the item descriptor for the proposed Medicare rebate for fetal MR. The non – CNS indications for fetal MR, while representing only about 20% of current clinical referrals, have very significant impact on planning of method (including EXIT), timing and location of delivery and perinatal surgery as well as fetal prognosis. It is these infants who most often have treatable conditions where surgical options and delivery planning, and not termination of pregnancy, are the critical clinical decisions that are informed by fetal MR during the prenatal period. The financial impact of including non – CNS applications of fetal MR for suspected structural abnormalities would be minimal and the inclusion of these additional applications would both reflect the current referral patterns for fetal MR in Australia and prevent disenfranchisement of women pregnant with fetuses likely to require perinatal surgery that would be aided by the additional information provided by fetal MR

## 17. Further information on MSAC

MSAC Terms of Reference and other information are available on the MSAC Website: [visit the MSAC website](#)