



Australian Government

Department of Health

RATIFIED PICO

Application 1608:

Amnion membrane (human tissue) for topical treatment of ophthalmic disorders (caused by disease and/or trauma to the cornea), and wound dressings for skin burns and ulcers on the craniofacial area, torso, and limbs

Summary of PICO/PPICO criteria to define the question(s) to be addressed in an Assessment Report to the Medical Services Advisory Committee (MSAC)

Component	Description
Patients	<p>Population 1: Ophthalmic conditions</p> <p>First line treatment: Ophthalmic condition where cells on the corneal surface are disrupted (including chemical trauma, chemical burns, thermal burns, radiation burns, Stevens Johnson Syndrome, toxic epidermal necrosis, surgery removing the epithelium of the cornea; e.g. pterygium surgery)</p> <p>Second line treatment: Other corneal wounds which have failed to heal</p>
Intervention	Amnion membrane tissue grafts
Comparator	<p>Supportive care (chemical trauma, chemical burns, thermal burns, radiation burns, Stevens-Johnson Syndrome, toxic epidermal necrosis, surgery removing the epithelium of the cornea excluding pterygium surgery, chronic corneal wounds)</p> <p>Conjunctiva autografting (pterygium surgery)</p>
Outcomes	<p><u>Patient relevant outcomes</u></p> <ul style="list-style-type: none"> • Any adverse events associated with amnion membrane, including infection rates and donor derived infections • Any adverse events associated with comparators, including infection rates • Wound healing (rate of frequency of complete healing; time to healing) • Visual acuity • Pain • Time to return to work/activity • Length of hospital stay • Disease recurrence (particularly for pterygium surgery) • Quality of life <p><u>Healthcare system outcomes</u></p> <ul style="list-style-type: none"> • Costs associated with the intervention, including resource use to deliver intervention and follow-up costs • Costs associated with the comparator, including resource use to deliver intervention and follow-up costs • Changes in utilisation of healthcare costs during follow-up period (for example: due to changes in hospitalisation rates and length; those required to treat adverse events)

Component	Description
Patients	Population 2: Chronic skin ulcers, where chronic is defined as unresponsive to treatment for at least six weeks
Intervention	Amnion membrane tissue grafts
Comparator	UrgoStart dressing (diabetic foot and venous insufficiency ulcers) Split thickness skin grafts (diabetic foot ulcers, venous insufficiency ulcers)
Outcomes	<p><u>Patient relevant outcomes</u></p> <ul style="list-style-type: none"> • Any adverse events associated with amnion membrane including any infection rates and donor derived infections • Any adverse events associated with comparators including any infection rates • Wound healing (change in wound size, rate of healing frequency of complete healing, time to healing) • Scarring and cosmesis outcomes • Pain • Patient movement • Limb salvage rates • Amputation rates • Time to return to work/activity • Length of hospital stay • Quality of life <p><u>Healthcare system outcomes</u></p> <ul style="list-style-type: none"> • Costs associated with the intervention including resource use to deliver intervention and follow-up costs • Costs associated with the comparator including resource use to deliver intervention and follow-up costs • Changes in utilisation of healthcare costs during follow-up period (for example: due to changes in hospitalisation rates and length; those required to treat adverse events)

Component	Description
Patients	<p>Population 3: Acute skin wounds</p> <ul style="list-style-type: none"> a) burns where patients require dermal substitute before skin grafting can take place b) patients with a graft donor site wound; c) patients requiring a skin graft fixator d) patients with toxic epidermal necrolysis skin lesions requiring dressing
Intervention	Amnion membrane tissue grafts
Comparator	<p>Dermal substitutes (Integra and Novosorb BTM) (Population 3a) Standard wound dressing (Population 3b) Traditional fixation methods (e.g. staples, stiches, micropoous tape) (Population 3c) Biobrane (Population 3d)</p>
Outcomes	<p><u>Patient-relevant outcomes</u></p> <ul style="list-style-type: none"> • Any adverse events associated with amnion membrane including any infection rates and donor derived infections • Any adverse events associated with comparators including any infection rates • Wound healing (change in wound size, rate of healing frequency of compete healing, time to healing) • Graft loss rates/graft take • Scarring and cosmesis outcomes • Pain • Patient movement • Time to return to work/activity • Length of hospital stay • Quality of life <p><u>Healthcare system outcomes</u></p> <ul style="list-style-type: none"> • Costs associated with the intervention, including resource use to deliver intervention and follow-up costs • Costs associated with the comparator, including resource use to deliver intervention and follow-up costs • Changes in utilisation of healthcare costs during follow-up period (for example: due to changes in hospitalisation rates and length; those required to treat adverse events)

Population

The Applicant proposed three populations:

1. Ophthalmic conditions:
 - a. First line treatment: Ophthalmic condition where cells on the corneal surface are disrupted (including chemical trauma, chemical burns, thermal burns, radiation burns, Stevens-Johnson Syndrome, toxic epidermal necrosis, surgery removing the epithelium of the cornea e.g. pterygium surgery)
 - b. Second line treatment: other corneal wounds which have failed to heal
2. Chronic ulcers where chronic is defined as unresponsive to treatment for at least six weeks
3. Acute wounds for:
 - a) burns where patients require dermal substitute before skin grafting can take place
 - b) patients with a graft donor site wound;
 - c) patients requiring a skin graft fixator
 - d) patients with toxic epidermal necrolysis skin lesions requiring dressing

PASC noted the application is seeking listing of amnion membrane (human tissue) on Part B of the Prostheses List (PL) and required a health technology assessment (HTA), as currently there are no similar amnion membrane products listed on Part B of the PL.

PASC noted the PICO included three (3) separate populations, each with subpopulations.

PASC noted that the assessment group sought clarification of whether the three patient populations presented as three separated PICOs should be considered as separate applications. PASC acknowledged the difficulty in assessing several populations with subgroups in a single submission. However, PASC was concerned that separating the application by populations may impact the ability of MSAC to provide HTA advice to the Prostheses List Advisory Committee (PLAC) on the suitability of listing amnion membrane on Part B of the PL. Therefore, PASC advised that the application should continue to progress as a single submission, ensuring subgroups analysis is carried out, where data permits.

Population 1: Ophthalmic conditions

Population 1 covers a range of ophthalmic conditions, which may cause the corneal surface to be disrupted. The corneal epithelium is comprised of five to seven layers of cells, which control corneal permeability to maintain the tear film. Generally, corneal-epithelium turnover is quick and rapid healing is possible (Lee, 2016). This is consistent with expert advice that, in normal circumstances, corneal wounds heal quickly. Expert advice is that amnion membrane products are most relevant for difficult cases where there is no clear therapeutic approach (Associate Professor of Ophthalmology, 2020). The expert also noted that the goal of treatment is a clear cornea and that difficult to treat cases lead to impaired vision or blindness if healing is not achieved.

PASC noted that Population 1 in the draft PICO defined the use of amnion membrane as a first line treatment in patients with disruption of the corneal surface due to: chemical, thermal and radiation burns; Stevens-Johnson Syndrome (SJS) and Toxic Epidermal Necrosis; pterygium surgery; or other ophthalmic surgeries where the cornea is removed. PASC noted that this population also proposed

the use of amnion membrane, a second line treatment in patients with chronic ophthalmic conditions where the corneal wound is refractory to treatment.

PASC advised that the use of amnion membrane in acute ophthalmic conditions (e.g. trauma) should be considered separately to its use in chronic ophthalmic conditions (e.g. SJS).

Chemical, thermal and radiation burns

Chemical and thermal burns to the eye most commonly occur in young men following accidental exposure (Hemmati and Colby, 2020). Burns to the eye represent a medical emergency and require immediate emergency response, including irrigation and normalisation of the ocular pH in the case of chemical burns. After transfer to hospital, acute care is provided based on the severity of the injury as determined in an ophthalmic exam.

Corneal damage can also be caused by radiation. Most commonly, this is due to ultraviolet (UV) light causing photokeratitis. Photokeratitis is often caused by exposure to reflected natural UV rays (e.g. reflected sun from snow, sand and water) or can be due to man-made UV rays (e.g. from sun bed or arc welding) (Porter and Pagan-Duran, 2020, Solano, 2019). Similarly, ionising radiation exposure (X-ray, radioactive isotopes and medical radioactive sources) can also lead to ophthalmic radiation burns which cause corneal damage. In some cases this can lead to scar formation and corneal opacification (Ingraham et al., 2003)

Burns can be categorised as (Hemmati and Colby, 2020):

- Grade 1: injury confined to corneal epithelium, cornea is totally clear
- Grade 2: mild corneal glaze, anterior chamber structures visible, focal limbal ischemia
- Grade 3: significant ischemia of limbus, profound corneal glaze prohibiting visibility of anterior chamber structures
- Grade 4: total loss of limbal stem cells, destruction of proximal conjunctival epithelium, corneal opaque and porcelainised.

The goal of treatment is to support corneal healing while decreasing pain, inflammation and infection (Associate Professor of Ophthalmology, 2020, Hemmati and Colby, 2020, Solano, 2019). Supportive care for all grade of injuries involves prophylactic antibiotics, topical steroids, topical cycloplegic agents and oral pain relief as required. For Grade 2-4 injuries oral tetracycline may be used to reduce corneal melting, in addition, debridement of necrotic tissue may be required. Steroids are used more frequently with higher grade injuries (four time per day for Grade 1 compared to hourly application for more severe injuries). Ophthalmic follow-up for patients would typically be every 2-3 days while an inpatient, then at 1-2 weeks post-discharge, transitioning to monthly appointments with the ophthalmologist as healing progresses. Patients would continue to receive ophthalmic follow-up 1-2 years post-injury.

Expert advice is that currently, amnion membrane is more established for patients who do not achieve satisfactory healing with 1-2 weeks of supportive care, but emerging research is that amnion may be indicated for acute use in Grade 2-4 injuries (Associate Professor of Ophthalmology, 2020).

Data from the Australian Institute of Health and Welfare (AIHW) indicates that 221 hospitalisation for eye burns were recorded in 2013/14 (AIHW et al., 2016). The grade of these injuries is not known; therefore, this presents an upper limit to the number of amnion membrane products that could be expected to be used in this subpopulation.

Stevens-Johnson Syndrome and Toxic Epidermal Necrosis

Stevens-Johnson Syndrome (SJS) is an inflammatory disorder which targets the skin and mucous membranes (Slentz and Hemmati, 2013). The disease is characterised by blistering and necrosis which can be life threatening. Toxic epidermal necrosis (TEN) is on the same disease spectrum as SJS, where SJS involved less than 10 per cent of the body, SJS-TEN complex involves 10 to 30 per cent of the body and TEN involves more than 30 per cent of the body (Sharma et al., 2016). Ocular manifestations occur in 50 to 80 per cent of patients with SJS or TEN (Sharma et al., 2016) and can be characterised as mild, moderate or severe according to the following (Hsu et al., 2012, Wander and Kroger, 2020):

- Mild/moderate: less than 1/3 lid margin involvement, conjunctival defects less than 1 cm and no corneal epithelial defects
- Severe: greater than 1/3 lid margin involvement, conjunctival defects greater than 1 cm or presence of corneal epithelial defects.

For both mild/moderate and severe cases standard ophthalmic care involves an ophthalmic examination within 24 hours, supportive treatment with topical antibiotics, cyclosporin twice daily and topical steroids 4-8 times per day (Hsu et al., 2012, Sharma et al., 2016, Slentz and Hemmati, 2013, Wander and Kroger, 2020). Expert advice is that patients would be treated as in-patients and require daily follow-up until the systemic disease is being well managed and corneal healing has occurred (Associate Professor of Ophthalmology, 2020).

Amnion membrane has been suggested as an adjunct to supportive care in the acute phase of SJS for both mild/moderate and severe forms of the disease (Sharma et al., 2016). Other authors have suggested amnion is more appropriately used as an adjunct for severe cases (Slentz and Hemmati, 2013, Wander and Kroger, 2020).

SJS and TEN are rare conditions, a 10-year retrospective review of all SJS and TEN cases diagnosed at a tertiary referral centre in New South Wales between 2006 and 2016 identified 42 patients (Chan and Cook, 2019). Similarly, a retrospective chart review of all cases treated at a tertiary hospital in South Australia between 2000 and 2017 identified 42 patients (Tran and Sidhu, 2019).

PASC advised that the submission should consider whether there is sufficient evidence to support amnion membrane use for all patients with SJS or only a subgroup of patients with more severe disease.

Pterygium

Pterygium is a fibrovascular growth of the bulbar conjunctiva that can extend over the cornea and cause irritation and impair vision (Noureddin and Yeung, 2016). Risk factors for pterygium include sunlight exposure, dusty or sandy environment and increasing age (BetterHealth, 2016).

Minor cases, where the principle issue is symptoms control (for irritation, mild pain and itching), can be treated with supportive care including eye drops or ointments to provide lubrication to the eye and reduce inflammation. If growth is significant such that discomfort is marked and/or vision is impaired then surgery involving conjunctiva autografting can be performed (VEI, 2020).

Conjunctival autografting involves excision of the pterygium and using the patient's own grafted conjunctiva to close the remaining defect (Noureddin and Yeung, 2016).

AIHW data from 2017/18 shows 9,013 excision of pterygium procedures were performed in Australia (AIHW, 2019). It is not known what level of severity these procedures represent; therefore, the number of patients potentially eligible for amnion membrane in this subpopulation is not known.

Other ophthalmic conditions

Amnion membrane may also be indicated for other types of surgery where the cornea is removed, for example ocular surface squama neoplasia removal. Sufficient cornea should be removed such that all involved tissue is removed as well as a clear margin of unaffected cells (Bunya and Chang, 2019). Expert advice is that post-surgery of this type, standard supportive care includes use of an eye patch, prophylactic antibiotics, topical steroids, topical cycloplegic agents and oral pain relief as required (Associate Professor of Ophthalmology, 2020).

Recent data suggest amnion membrane may not be as effective as conjunctival autografting except where large or double headed or where conjunctiva cannot be harvested (Noureddin and Yeung, 2016). This is consistent with expert advice that generally, when portions of the cornea are surgically removed, supportive care is enough for healing in most cases except those where extensive corneal removal is required (Associate Professor of Ophthalmology, 2020).

PASC advised that the submission should consider whether amnion membrane is indicated for all patients undergoing surgical corneal removal or only a subgroup of patients undergoing extensive removal.

Chronic ophthalmic wounds

In addition to conditions listed above, the Applicant stated that amnion membrane is also suitable for any ophthalmic wound which is refractory to healing. Corneal wounds may become chronic wounds due to epithelial or stem cell deficiency, presence of inflammatory disease (e.g. due to keratoconjunctivitis sicca), neurotrophic disease (for example due to diabetes or nerve damage from ocular surgery) or due to mechanical factors, such as abnormal lid pathology, which can lead to epithelial trauma and stem cell attrition (Gupta et al., 2014). Expert advice is that corneal healing would be expected to be observed within the first month of treatment; failure to heal in this timeframe may indicate amnion treatment is appropriate (Associate Professor of Ophthalmology, 2020). These wounds would be treated with standard supportive measures including topical steroids, lubrication and oral tetracyclines (Gupta et al., 2014).

Population 2: Chronic skin wounds

For this Application, chronic wounds are defined as those that have been unresponsive to treatment following at least 12 weeks of standard wound care.

PASC noted that the draft PICO proposed the use of amnion membrane in chronic skin wounds defined as unresponsive to treatment for at least 6 weeks. PASC considered that a chronic skin wound is more appropriately defined as a wound that is refractory to treatment after 12 weeks of initial therapy. PASC also considered 12 weeks of standard therapy appropriate before commencing treatment venous ulcers with amnion membrane.

PASC considered whether amnion membrane is suitable for patients with deep wounds where bone or tendon are exposed. PASC advised the potential use of amnion membrane as a bridge to appropriate treatment in these patients requires expert advice and consideration of whether

evidence is available to demonstrate this is an appropriate treatment (i.e. safe and effective) during the evaluation phase.

Chronic skin wounds represent a considerable health and economic burden in Australia, with more than 400,000 Australians affected and health-care related costs in excess of \$3.5 billion (2% national health expenditure) (McCosker et al., 2019, Sussman, 2014).

The underlying aetiology of the wound is a key determinant of management, for this Application, wounds have been classified as (Professor of Vascular Surgery, 2020, Sussman, 2014):

- Venous insufficiency ulcers
- Arterial insufficiency ulcers
- Diabetic foot ulcers.

Venous insufficiency ulcers

Venous insufficiency ulcers are caused by a reduction in venous circulation in the lower limbs, which prohibits usual circulation of blood through the leg veins. The resulting increased venous pressure leads to pitting oedema; when an injury occurs, there is insufficient blood supply for healing to occur and an ulcer results (Sussman, 2014). Risk factors for this type of wound includes obesity, prior deep vein thrombosis and poor mobility (Sussman, 2014). Compression therapy from foot to knee should be employed as well as lower limb exercise and avoidance of long periods of standing (Plastic Surgeon, 2020, Professor of Vascular Surgery, 2020, Sussman, 2014, SIGN, 2010).

Venous insufficiency ulcers are estimated to occur in 48,000 Australian annually (AusHSI, 2017). Healing rates from standard care range from 30-60% with 24 weeks of treatment and 70-85% with one year of treatment (Margolis et al., 1999).

Arterial insufficiency ulcers

Arterial insufficiency ulcers typically present on the ankle and foot and are associated with ischemic pain. Risk factors of arterial insufficiency ulcers are poorly controlled diabetes and smoking. These ulcers should be assessed for surgery to address revascularisation, adequate pain management should be provided and should not be treated with compression therapy (Plastic Surgeon, 2020, Professor of Vascular Surgery, 2020, Sussman, 2014).

No population prevalence data for arterial insufficiency ulcers was identified; it is estimated that these types of wound make up 3-19% of lower extremity ulcers, 1-11% of all types of wound (including chronic, surgical and traumatic) (McCosker et al., 2019). Specifically considering chronic skin wounds, arterial insufficiency ulcers are estimated to comprise 1% of the total (estimated as being 400,000) (AusHSI, 2017). This would give an estimated 4,000 chronic arterial ulcers annually.

Diabetic foot ulcers

Diabetes mellitus causes nerve damage (neuropathy) in the feet and lower limbs resulting in reduced or loss of sensation which may lead to injuries being unnoticed and progressing to a more advanced stage before being treated (Alavi et al., 2014, DFA, 2020).

Diabetes is also associated with an increased risk of ischaemic arterial disease (see above). Approximately 20% of patients with diabetes are at increased risk of developing a diabetic foot ulcer (McCosker et al., 2019). Initial management should include addressing overall diabetes management, offloading and surgery for revascularisation if relevant).

In addition to the above wound-specific management, all wounds should be debrided, treated for infection if present and nutritional factors (such as vitamin deficiency) should be addressed (Professor of Vascular Surgery, 2020, Plastic Surgeon, 2020).

Wounds should be dressed to obtain the optimum moist environment for wound healing. Expert advice is that a range of first-line dressings are used routinely in Australia including alginate, film, foam, hydrocolloid and hydrogel dressings (Professor of Vascular Surgery, 2020). The optimum dressing for each patient will also depend on wound type, depth, level of exudate, patient comfort and costs (IWGDF, 2019, Sussman, 2014).

It is estimated that 7-17% of diabetic foot ulcers fail to heal after initial treatment and would therefore be considered chronic. This estimate is based on an estimated 1.7 million Australians having diabetes, 4-10% of these patients developing an ulcer and reported data that approximately 3% of the 400,000 estimated chronic skin wounds in Australia are diabetic foot ulcers (Alexiadou and Doupis, 2012, Diabetes Australia, 2020, AusHSI, 2017). Advice from the Department of Health Medical Advisor is that this estimate is reasonable (DoH Medical Advisor, 2020a). This would give an upper limit of 12,000 patients annually for this part of the proposed population.

Population 3: Patients with acute wounds (i.e. burns where patients require a dermal substitute before skin grafting can take place); and (and added since receipt of the Application) treatment of graft site; or skin graft fixator and toxic epidermal necrolysis

PASC noted that Population 3 defined patients with acute wounds, including patients with burns that require a dermal substitute before skin grafting and that the applicant had proposed three additional sub-populations: patients who require treatment of a skin graft donor site; patients who require a skin graft fixator and patients with toxic epidermal necrolysis. The Summary PICO was updated to reflect these three subpopulations.

Burns where patients require a dermal substitute before skin grafting can take place

Management of burns in Australia involves emergency response, transfer to hospital and assessment. Treatment post-presentation to emergency depends on the severity of the burn. Minor burns may be managed in an outpatient setting and are expected to heal in 10-14 days. More serious burns require referral to specialist burns units. Referral criteria are (BRANZ, 2019):

- burns greater than 10 per cent of total body surface area;
- burns of special areas—face, hands, feet, genitalia, perineum, and major joints;
- full-thickness burns greater than five per cent of TBSA;
- electrical burns;
- chemical burns;
- burns with an associated inhalation injury;
- circumferential burns of the limbs or chest;
- burns in the very young or very old, or pregnant;
- burns in people with pre-existing medical disorders that could complicate management, prolong recovery, or increase mortality;
- burns with associated trauma; and
- non-accidental burns

Debridement and split skin grafting are recommended for all full thickness burns and most non-superficial partial thickness burns. Expert advice is that dermal substitutes such as amnion membrane do not replace skin grafts under current Australian management of burns. Instead these products are used as a bridge to skin grafts in patients where immediate skin grafting is not possible or where additional support is required for the skin graft. This may include the following sub-populations (Plastic and Reconstructive Surgeon, 2018, Plastic Surgeon, 2020):

- Patients with a burn requiring a skin graft where the patient is not able to undergo immediate grafting (due to large burn surface area or who require stabilisation)
- Patients with a burn in a priority area (for example the face, hands, feet, genitalia) where a dermal substitute is required for cosmetic outcomes
- Patients for whom skin contracture may be problematic
- Where radiotherapy is anticipated post-operatively.

Data on the number of procedures from the Burns Registry of Australia and New Zealand (BRANZ) for the 2017/18 financial year is reported in Table 1. A total of 1658 skin graft procedures were performed (BRANZ, 2019). This would be the maximum potential utilisation of amnion membrane in this population. However, expert advice is that most patients do not require a dermal substitute prior to skin grafting; therefore, expected utilisation of amnion membrane, if adopted into clinical practice, would be much lower (less than 5-10% of total skin graft patients). This is reflected in the utilisation figures shown in Table 1; where only 1% of adult patients required Integra (a comparator to amnion membrane in this population; see Comparator section).

Table 1 Burns procedures, 2017-2018

Procedure	Paediatric patients n (%)	Adult patients n (%)
Debridement and skin grafting	336 (46%)	1322 (59%)
Debridement and temporary skin closure product e.g. Biobrane™	93 (13%)	319 (14%)
Debridement and skin cell product	73 (10%)	200 (9%)
Debridement only	224 (31%)	371 (17%)
Debridement and reconstructive product eg Integra™	2 (0%)	12 (1%)
Debridement and temporary skin closure with cadaver skin	5 (1%)	43 (2%)

Source: BRANZ Annual report (BRANZ, 2019)

Patients with a graft donor site wound

Most skin-graft treatments, for example those used for burns, are autografts (see Table 1); either split-skin thickness or full thickness depth may be taken for the graft (Romanelli et al., 2019). Therefore, as well as treating the burn or wound, the graft site also represents an acute wound which must be managed. Amnion membrane has been investigated as a treatment for these wounds (Abul et al., 2020, Eskandarlou et al., 2016). Primary dressing type is selected dependent on many factors including wear time, exudate management, adhesiveness, infection control patient comfort, pain, odour control, cost and ensuring an optimum wound healing environment (Romanelli et al., 2019). Wound healing is expected in 10 to 21 days depending on the depth and area of skin removed (Romanelli et al., 2019, VABS, 2019b). For some patients, healing may be delayed due to age, comorbidities (diabetes, cardiovascular issues, renal insufficiency), smoking and poor nutritional status (Romanelli et al., 2019). Ensuring adequate vascularisation for healing at the graft donor site is also an important factor in wound healing (Romanelli et al., 2019).

PASC noted the assessment group is still awaiting expert advice on whether it is appropriate to consider use of amnion membrane in all patients with a graft-donor site wound, or whether it should be limited to patients for whom healing is expected (or observed to be) delayed (e.g. due to underlying patient co-morbidity).

The assessment group noted that advice on this matter was not received in time for the development of this PICO and as such, it is suggested the submission goes on to assess what evidence is available for this population and clarify this issue with an expert in this area during the evaluation phase.

Patients requiring skin graft fixators

Skin graft adherence to the wound bed is critical to ensure the graft revascularizes and the wound heals (Thorton and Gosman, 2004). Graft fixation is used to immobilise the graft in the wound bed, preventing graft mobilisation and loss (Mohammadi et al., 2013). Skin graft fixation methods may include stitches, staples, microporous tape and topical negative pressure dressings (Mohammadi et al., 2013, Kamolz et al., 2014, Ramos, 2007). Recent literature has investigated amnion membrane as a skin graft fixator, replacing other graft fixation techniques (Mohammadi et al., 2013).

It is not known how many patients undergoing a skin graft may be eligible for amnion fixation.

Patients with toxic epidermal necrolysis skin lesions requiring dressing

As described above for Population 1, TEN is characterised by blistering and necrosis which can be life threatening. Patients with TEN are usually treated in an intensive care and burns unit (Ngan et al., 2016). Standard care for skin lesions in TEN and involves leaving and skin blebs and blisters intact to act as a natural dressing (Klama-Baryla et al., 2020). Necrotic tissue needs to be removed and wounds dressed; BioBrane is reported as a skin substitute which can be used to dress acute wounds in these patients (Klama-Baryla et al., 2020). The acute phase of TEN lasts from 8 to 12 days, with reepithelization taking several weeks to be complete (Ngan et al., 2016). Amnion membrane as an alternate treatment for these dermatological lesions (Klama-Baryla et al., 2020, Klama-Baryla et al., 2018).

Rationale

The proposed populations cover a large number of potential patients; however, it is not clear if all patients in the proposed populations could and/or should receive amnion membrane.

For Population 1, it may be appropriate to investigate whether there is evidence to support limiting amnion membrane use to patients with moderate/severe forms of the SJS, moderate/severe burns and patients undergoing extensive corneal removal surgery.

For Population 2, the two experts advising on this PICO were explicitly asked if the current definition for Population 2 could be further refined to identify and target subpopulations for whom amnion membrane may provide greater benefit or be better targeted. Advice from experts was that the current definition represents patients with 'difficult to heal' wounds; however, expert advice noted that amnion membrane is not suitable for patients with deep wounds where bone and/or tendon are exposed (DoH identified Expert, 2020, Plastic Surgeon, 2020). No other key subpopulations for inclusion or exclusion were identified by experts.

However, for a prior dehydrated amnion membrane application, PASC previously suggested that "one clear subpopulation could be patients with wounds that expose bone or tendon."

PASC addressed the issue during its consideration of Population 2: Chronic skin wounds.

For Population 2, there is some discrepancy as to how a “chronic wound” should be defined. Expert advice is that “unresponsive to treatment” would be wounds that have failed to reduce in size by 40-50% during the initial 6 weeks (Professor of Vascular Surgery, 2020, Plastic Surgeon, 2020). The Applicant agreed this definition is appropriate. Advice from an expert provided by the Department of Health is that 12 weeks may be a better cut-off, to determine if a wound is “chronic” (DoH identified Expert, 2020). Further, it is noted that, in an amnion membrane application previously considered by PASC, a chronic wound was defined as “failure to show satisfactory healing after > 4 weeks of standard wound care”.

PASC addressed the issue during its consideration of Population 2: Chronic skin wounds.

After discussion with the Applicant, Population 3 was refined from that proposed (“patients with burns”) to “patients with acute wounds, including: burns where patients require a dermal substitute before skin grafting can take place; treatment of graft site; skin graft fixator; and toxic epidermal necrolysis”. This change was based on expert advice (Plastic and Reconstructive Surgeon, 2018, Plastic Surgeon, 2020), and communication from the Applicant (email received 4 March 2020).

Intervention

The proposed intervention is any amnion membrane product.

This definition of the intervention differs from that proposed in the Application Form. The Applicant proposed cryopreserved amnion membrane as the intervention for assessment. Following advice from a Department of Health Medical Advisor, this was broadened to include any amnion membrane product, to ensure sufficient evidence was available for the assessment (DoH Medical Advisor, 2020b). Other amnion membrane products available in Australia are discussed under “Rationale” below.

PASC confirmed the proposed intervention as any amnion membrane product.

Amnion membrane is purported to promote healing in a variety of ways including (Application Form page 20):

- providing a scaffold for tissue to regenerate around and providing protection from friction and a moist wound environment;
- promoting re-epithelisation due to the collagen containing membrane providing a substrate for epithelium cells to grown on;
- providing an analgesic effect by coving nerve endings;
- supressing inflammation due to cytokine production and trapping inflammatory cells;
- inhibiting fibroblast proliferation and differentiation reducing scarring;
- reducing unwanted vascularisation in the eye by inhibiting blood vessel formation;
- providing a physical barrier to infection due to antimicrobial properties; and,
- avoiding immunological rejection due to an absence of HLA antigens.

The Applicant described the process for manufacturing cryopreserved amnion membrane in the Application Form (page 21). Cryopreserved amnion membrane is obtained from consenting donors undergoing full-term elective caesarean section births.

The donor is assessed in accordance with Therapeutic Goods Order 88. The tissue is treated with antibiotics and antifungals (streptomycin, penicillin and amphotericin). The amnion membrane is then cryopreserved in dimethyl sulfoxide 10% (DMSO), and stored at -80 degrees Celsius. The tissue is quarantined for 3 months before it can be released. Amnion membrane is provided on a nitrocellulose backing paper and is available in three sizes (5 cm diameter circle; 5x10 cm; and 10x10 cm pieces). Following release, the amnion membrane has an expiry of 12 months, if kept frozen. The product is provided with a description of the serological and microbiological status of the graft, and documentation confirming the product is not sterile and therefore may pose a minimal risk to the recipient.

Amnion membrane is requested by clinicians wishing to use the product. Requests are processed on a first come/first served basis, with emergency requests given priority. Requests from the private and public health sectors are not differentiated for access. The Applicant noted that the main limit to supply is authorisation of donors.

The cryopreserved amnion membrane was listed on the Australian Register of Therapeutic Goods (ARTG) in 2018 (Table 2).

Table 2 ARTG Listing for cryopreserved amnion

ARTG number Start date	Sponsor	Category	Product name	Product type	Intended use
303207 18/05/2019	South Eastern Sydney Local Health District	Biological Included Class 2	Amniotic membrane, cryopreserved	Amnion	Treatment of ophthalmic disorder/disease/trauma, or as a wound dressing

Source: ARTG [Website](#).

For ophthalmic use, the Applicant noted that it likely to occur in an operating theatre, due to the equipment required for ophthalmic procedures. For wounds, amnion may be placed in an operating theatre, following surgical debridement, or in a treatment room, depending on the patient circumstances.

The Prosthesis List Rules state that items listed on the Prosthesis List only attract benefits if used in a hospital or hospital-replacement setting. Advice from experts is that, for Population 1 (ophthalmic conditions), and Population 3 (burns), all patients would be expected to be treated in hospital. For Population 2, expert advice is that the treatment setting would be split between hospital and community settings, but it is reasonable to assume approximately 50% of patients with a 'difficult to heal' chronic skin wound would be treated in hospital (Plastic Surgeon, 2020, Professor of Vascular Surgery, 2020).

PASC confirmed that, as a product listed on the Prosthesis List, amnion membrane would be intended for use as treatment in a hospital or hospital substitute setting. PASC requested clarification from the Department about the definition of 'hospital substitute', particularly considering the likely use in community settings. Hospital-substitute treatment means general treatment that:

- a) substitute for an episode of hospital treatment; and*
- b) is any of, or any combination of, nursing, medical, surgical, podiatric surgical, diagnostic, therapeutic, prosthetic, pharmacological, pathology or other services or goods intended to manage a disease, injury or condition; and*

c) *is not specified in the Private Health Insurance (Complying Product) Rules as a treatment that is excluded from this definition.*

The amnion membrane is absorbed or sloughs off during wound healing, over 7-21 days. If healing is progressing, but not complete, another amnion membrane application may be required (Application Form page 24; and Plastic Surgeon, 2020).

The Applicant advised that, since February 2019, there have been 150 requests for cryopreserved amnion membrane product for ophthalmic conditions. The Applicant stated that 150 grafts were released in 2019, to 68 surgeons across Australia (85% in the private sector), for ophthalmic use only.

Between 2016 and 2019, cryopreserved amnion membrane was obtained from New Zealand Eye Bank under the Therapeutic Goods Administration (TGA) Special Access Scheme; 157 grafts were obtained for ophthalmic conditions in 2018 (Application Form, page 21).

Prior to 2016, cryopreserved amnion membrane was listed on the Australian Human Tissues Prostheses List (billing code LEM03). The Victorian Eye Bank ceased production of amnion membrane due to a decline in usage in Victoria, and due to costs associated with regulatory processes, namely implementation of the TGA Biological Framework (Application Form, page 21). Expert advice is that, while amnion membrane use in Australia for ophthalmic conditions is currently limited, it may increase if a Prostheses Listing was obtained (Associate Professor of Ophthalmology, 2020).

Expert advice from Plastic and Vascular Surgeons is that amnion membrane products are currently not used in Australia to treat chronic or acute skin wounds (Plastic Surgeon, 2020, Professor of Vascular Surgery, 2020). This may change if high-level evidence supporting safety, effectiveness and cost effectiveness is identified, and if the product is eligible for funding. Under those circumstances, it is expected that amnion membrane would be used (Plastic Surgeon, 2020, Professor of Vascular Surgery, 2020).

Rationale

The current Application (1608) focused on cryopreserved amnion membrane. As discussed above, advice from the Department of Health Medical Advisor was that all forms of amnion membrane products (e.g. dehydrated amnion membrane products) should be included in the assessment, to ensure sufficient evidence is available (DoH Medical Advisor, 2020b).

In addition to the cryopreserved amnion membrane product discussed above, there are six other products listed under ARTG number 307979, which are dehydrated amnion membrane-based products used for wound healing (Table 3). Two additional products are also listed under this number - EpiFix Injectable and AmnioFix Injectable. These are injectable amnion membrane treatments for chronic plantar fasciitis, and are not relevant to this application.

Table 3 ARTG Listing for cryopreserved amnion

ARTG number Start date	Sponsor	Category	Product name	Product type	Intended use
307979 08/08/2018	Vicki Partridge Pty Ltd	Biological Included Class 2	Foetal membranes,	Amnion	For treatment of acute and

ARTG number Start date	Sponsor	Category	Product name	Product type	Intended use
			dehydrated, irradiated (EpiFix, AmnioFix, EpiFix Fenestrated, EpiXL, EpiFix Mesh, AmnioFix Wrap)		chronic wounds to enhance healing

Source: ARTG [Website](#).

The Applicant claimed that cryopreserved amnion may have better efficacy than dehydrated. Forms of amnions. Therefore, the Assessment Group suggests that if sufficient evidence is available, the assessment phase should investigate whether different forms of amnion membrane product have differing safety and effectiveness if evidence permits this analysis.

PASC agreed with the assessment group that the submission should investigate whether different forms of amnion membrane (e.g. cryopreserved or dehydrated) have differing safety and effectiveness, if evidence permits this analysis.

It is not clear how frequently amnion needs to be re-applied. The Applicant advised that re-application may be required every 7-21 days. The Assessment Group suggests that the assessment phase should look at available data on re-application for each subpopulation, and the economic evaluation should undertake sensitivity analysis to explore this issue.

PASC agreed with the assessment group that the submission should include data on the frequency of reapplication of amnion membrane, and explore this in sensitivity analyses in the economic evaluation.

Comparator

Population 1: Ophthalmic conditions

Expert advice is that the most appropriate comparator for the SJS, TEN, burns and chronic corneal wound subpopulations would be supportive care. As described in the Population section of this PICO, this entails a combination of topical steroids, topical cycloplegic agents, pain relief, oral tetracycline and tissue debridement. The exact combination of treatments and frequency of application is dependent on the nature of the injury (Associate Professor of Ophthalmology, 2020).

For pterygium surgery, the most relevant comparator would be conjunctival autograft (Noureddin and Yeung, 2016). For other corneal surgeries, the most relevant comparator would be continued supportive care (Associate Professor of Ophthalmology, 2020).

PASC confirmed the proposed comparators.

Population 2: Chronic skin wounds

For Population 2 the proposed comparators are:

- UrgoStart dressing (diabetic foot and venous insufficiency ulcers)
- Split thickness skin grafts (diabetic foot ulcers, venous insufficiency ulcers)

For venous insufficiency ulcers and diabetic foot ulcers, expert advice is that the most appropriate comparator is either use of the UrgoStart dressing or skin grafts. Expert advice is that the most relevant guidelines used in Australia to determine care for chronic skin wounds are the recently published International Working Group on the Diabetic Foot (IWGDF) Guidelines: Wound Healing Interventions Guideline (IWGDF, 2019).

UrgoStart is an interactive sucrose-octasulfate impregnated dressing, which has recently been shown to improve wound healing compared to non-interactive dressings in chronic diabetic and venous insufficiency ulcers in a multicentre, double blind RCT (Edmonds et al., 2018). The dressing is designed to create a moist wound environment using a technology-lipido-colloid layer, which promotes healing as well as inhibit protease activity via the nano-oligosaccharide factor (NICE, 2019b).

The use of the UrgoStart has recently been recommended by the National Institute for Health and Care Excellence (NICE) Guidelines for use in venous insufficiency and diabetic foot ulcers (NICE, 2019b), as well as being recommended in the IWGDF Guidelines (IWGDF, 2019). Expert advice is that this would be an appropriate comparator for both diabetic foot ulcers and venous insufficiency ulcers and that the product is currently used in Australia for these types of chronic skin wound (Professor of Vascular Surgery, 2020).

UrgoStart is listed on the ARTG (Table 4) and advice from the manufacturer is that the dressing is readily available in Australia and is listed on the majority of State Department of Health contracts (UrgoStart Manufacturer, 2020).

Table 4 ARTG Listing for UrgoStart

ARTG number Start date	Sponsor	Category	Product name	Product type	Intended use
134240 22/12/2006	Bayport Brands Pty Ltd	Medical Device Included Class IIB	Dressing, hydrogel	Single device product	Treatment of low to high exudative wounds, such as acute wounds (burns, dermabrasions etc.), chronic wounds (leg ulcers, pressure ulcers, diabetes ulcers etc.), and skin lesions caused by congenital epidermolysis bullosa

Source: ARTG [Website](#).

Advice from a plastic surgeon is that split thickness skin grafts would also be an appropriate comparator for diabetic foot ulcers and venous insufficiency ulcers and are currently used routinely for these types of chronic skin wounds (Plastic Surgeon, 2020).

Split thickness skin grafts involve the transfer of skin from donor site on the patient's body to the wound. Skin grafts provide protection to the wound, maintain temperature and prevent water loss like normal skin; however, they do not have blood supply and are reliant on the vascularisation of the wound bed for growth (Braza and Fahrenkopf, 2019). MBS items relevant to split-thickness skin grafts for chronic skin wounds are listed below. MBS item 45400 was claimed 923 times in 2018/19 while item 45403 was claimed 496 times.

Table 5 MBS listing for items 45400 and 45403

Group T8 – Surgical Operations Subgroup 13 – Plastic and Reconstructive Surgery Subheading 3 – Free Grafts	
45400 FREE GRAFTING (split skin) of a granulating area, small Multiple Operation Rule (Anaes.) Fee: \$208.00 Benefit: 75% = \$156.00 85% = \$176.80	
Group T8 – Surgical Operations Subgroup 13 – Plastic and Reconstructive Surgery Subheading 3 – Free Grafts	
45403 FREE GRAFTING (split skin) of a granulating area, extensive Multiple Operation Rule (Anaes.) (Assist.) Fee: \$414 Benefit: 75% = \$310.50 85% = \$351.90	

Source: MBS Online [website](#)

There is some evidence that skin grafts may improve healing in diabetic foot ulcers compared to standard wound care and NICE Guidelines recommend these may be used on the advice of the multidisciplinary foot care service (NICE, 2019a).

For venous insufficiency ulcers, the Scottish Intercollegiate Guidelines Network (SIGN) management of chronic venous leg ulcers guidelines do not recommend use of split skin grafts as there was

insufficient evidence showing an improvement in healing over standard care for chronic skin wounds (SIGN, 2010).

For arterial insufficiency ulcers, the key component of care is improving vascularisation; (VSGBI, 2020, Broderick et al., 2020)

Therefore, the most appropriate comparator appears to be standard wound care as described in Population section.

PASC confirmed the proposed comparators.

PASC suggested the assessment group could include skin grafts as an additional comparator for the chronic venous insufficiency ulcer population, if there is sufficient evidence to permit this comparison. The PASC also noted the use of skin grafts should be included towards the end of any treatment algorithm. The comparators have been updated to reflect PASC's advice.

Population 3: Acute skin wounds

3a Burns where patients require a dermal substitute before skin grafting can take place

Clinical feedback is that dermal substitutes are the most relevant comparator to amnion membrane in this population.

In Australia there are two dermal substitutes which are used to provide a bridge to skin grafts in patients with burns, Integra™ (Life Sciences Corp, Plainsboro, NJ) and NovoSorb™ Biodegradable Temporising Matrix (BTM) (PolyNovo Biomaterials Pty Ltd, Melbourne, Australia).

Integra is a dermal regeneration template constructed from bovine collagen and shark chondroitin-6-sulphate (Lohana et al., 2014). The structure provides a scaffold for neodermis formation. Australian guidelines state that Integra should only be applied by a burns medical specialist and is indicated for full thickness burns over flexor joints (Connolly, 2014).

Novosorb-BTM is a synthetic dermal replacement scaffold comprised of polyurethane open-cell foam (Wagstaff et al., 2015, Greenwood et al., 2018). The dressing is intended to: temporise extensively debrided wounds before skin grafting can take place; sustain grafts once integrated; integrate vascular tissue to create a neodermis; and, to reduce wound contraction (Wagstaff et al., 2015).

Both products are listed on the ARTG (Table 6).

Table 6 ARTG Listing for Integra and Novosorb-BTM

ARTG number & Start date	Sponsor	Category	Product name	Product type	Intended use
158796 27/01/2009	Integra Neurosciences Pty Ltd	Medical Device Included Class III	Integra Dermal Regeneration Template single layer - Skin regeneration template, human-/animal-derived	Single Device Product	To add extra thickness where required (to the Integra bi-layer dermal replacement) for the postexcisional treatment of full thickness and partial-thickness injuries where sufficient autograft is not available at the time of excision or not desirable due to the physiological condition of the patient. It is also indicated for use in reconstruction of postexcisional, full-thickness defects of the integument where there is, in the opinion of the treating surgeon, a potential benefit to the patient by improving the reconstructive outcome or decreasing their mortality/morbidity
308217 14/08/2018	PolyNovo Biomaterials Pty Ltd	Medical Device Included Class III	NovoSorb BTM - Dressing, absorbable	Single Device Product	Temporize dermal injuries, where the dermis has been decimated or lost, and to facilitate dermal repair by providing temporary closure of the wound and a scaffold for the generation of a neodermis

Source: ARTG [Website](#).

3b Patients with a graft donor site wound

The Victorian Adult Burns Service at the Alfred Hospital reported that graft-site wounds are usually dressed post-operatively, with xeroform and a secondary gauze layer (VABS, 2019b). Xeroform is a non-adhesive paraffin dressing. Other dressings used for the graft donor site may include foam, hydrocolloid, silicone membrane, alginate, and absorbent acrylic dressings, with gauze or foam as secondary dressings (Romanelli et al., 2019).

Standard wound dressing is therefore suggested as the most appropriate comparator for this subpopulation, as currently defined.

3c Patients requiring a skin graft fixator

For skin graft fixation, literature review indicated that traditional methods of graft-fixation include either use of staples, stitches and microporous tape (Mohammadi et al., 2013, Kamolz et al., 2014, Ramos, 2007). One study was identified where amnion has been compared to staples (Mohammadi et al., 2013). Therefore, it is suggested that traditional fixation methods are be the most appropriate comparators.

Recent literature has investigated the use of negative pressure dressing for skin-graft fixation. It is not known whether this technique is commonly used in Australia.

3d Patients with toxic epidermal necrolysis skin lesions requiring dressing

For patients with TEN, the suggested comparator to amnion membrane is Biobrane, a skin substitute used in Australia for superficial burn injuries. Biobrane contains pig collagen and provides wound closure and supports epithelisation (Ngan et al., 2016, VABS, 2019a).

PASC confirmed the proposed comparators.

For the three new subpopulations in Population 3 (3b, 3c and 3d), PASC agreed with the suggested comparators from the assessment group, and agreed that expert advice was required on traditional skin graft fixation methods.

The Assessment Group noted that expert advice has been sought, as to the current standard of care for skin graft fixation in Australia, however it was not received prior to finalising this PICO. It is recommended that the assessment phase should investigate what comparators are used in the literature and confer with an expert to ensure these are relevant to Australian clinical practice.

Rationale

Ophthalmic indications

Expert advice noted that some other rare treatments could be used for difficult to heal ophthalmic injuries (for example stem cell transplants or surgery to semi-permanently close the eye; however, these are not standard practice in Australia and therefore should not constitute comparators for the assessment (Plastic and Reconstructive Surgeon, 2018).

Chronic wounds

Many other skin substitute products are available for treating chronic wounds. Expert advice is that these are not routinely used in Australia; therefore, these products have not been included as comparators (Professor of Vascular Surgery, 2020). Further, use of these products is not recommended by IWGDF guidelines (IWGDF, 2019). NICE guidelines state these can be used for diabetic foot ulcers but only on the advice of the multidisciplinary foot care service (NICE, 2019a).

Negative pressure wound therapy is only recommended for post-surgical wounds in patients with diabetic ulcers (IWGDF, 2019, NICE, 2019a)

Both NICE and IWGDF Guidelines do not recommend the use electrical stimulation therapy, growth factors and hyperbaric oxygen therapy (IWGDF, 2019, McCosker et al., 2019).

Burns

For Population 3, expert advice is that BioBrane and Suprathel are indicated for use in superficial burns and are therefore not suitable comparators to amnion membrane in the proposed population for patients with burns (Plastic and Reconstructive Surgeon, 2018).

Outcomes

Patient-relevant outcomes

Population 1: Ophthalmic conditions

- Any adverse events associated with amnion membrane including any infection rates and donor derived infections
- Any adverse events associated with comparators including any infection rates
- Wound healing (rate of healing frequency of complete healing, time to healing)
- Visual acuity
- Pain
- Time to return to work/activity
- Length of hospital stay
- Disease recurrence (particularly for pterygium surgery)
- Quality of life

Population 2: Chronic skin wounds

- Any adverse events associated with amnion membrane including any infection rates and donor derived infections
- Any adverse events associated with comparators including any infection rates
- Wound healing (change in wound size, rate of healing frequency of complete healing, time to healing)
- Scarring and cosmesis outcomes
- Pain
- Patient movement
- Limb salvage rates
- Amputation rates
- Time to return to work/activity
- Length of hospital stay
- Quality of life

Population 3: Acute skin wounds

- Any adverse events associated with amnion membrane including any infection rates and donor derived infections
- Any adverse events associated with comparators including any infection rates
- Wound healing (change in wound size, rate of healing frequency of complete healing, time to healing)
- Graft loss rates/graft take
- Scarring and cosmesis outcomes
- Pain
- Patient movement
- Time to return to work/activity
- Length of hospital stay
- Quality of life

Healthcare system outcomes (for all three populations)

- Costs associated with the intervention including resource use to deliver intervention and follow-up costs
- Costs associated with the comparator including resource use to deliver intervention and follow-up costs
- Changes in utilisation of healthcare costs during follow-up period (for example due to changes in hospitalisation rates and lengths, those required to treat adverse events)

PASC confirmed that the proposed outcomes were appropriate.

Other considerations

It is suggested that the assessment report also collects/presents and analyses data on:

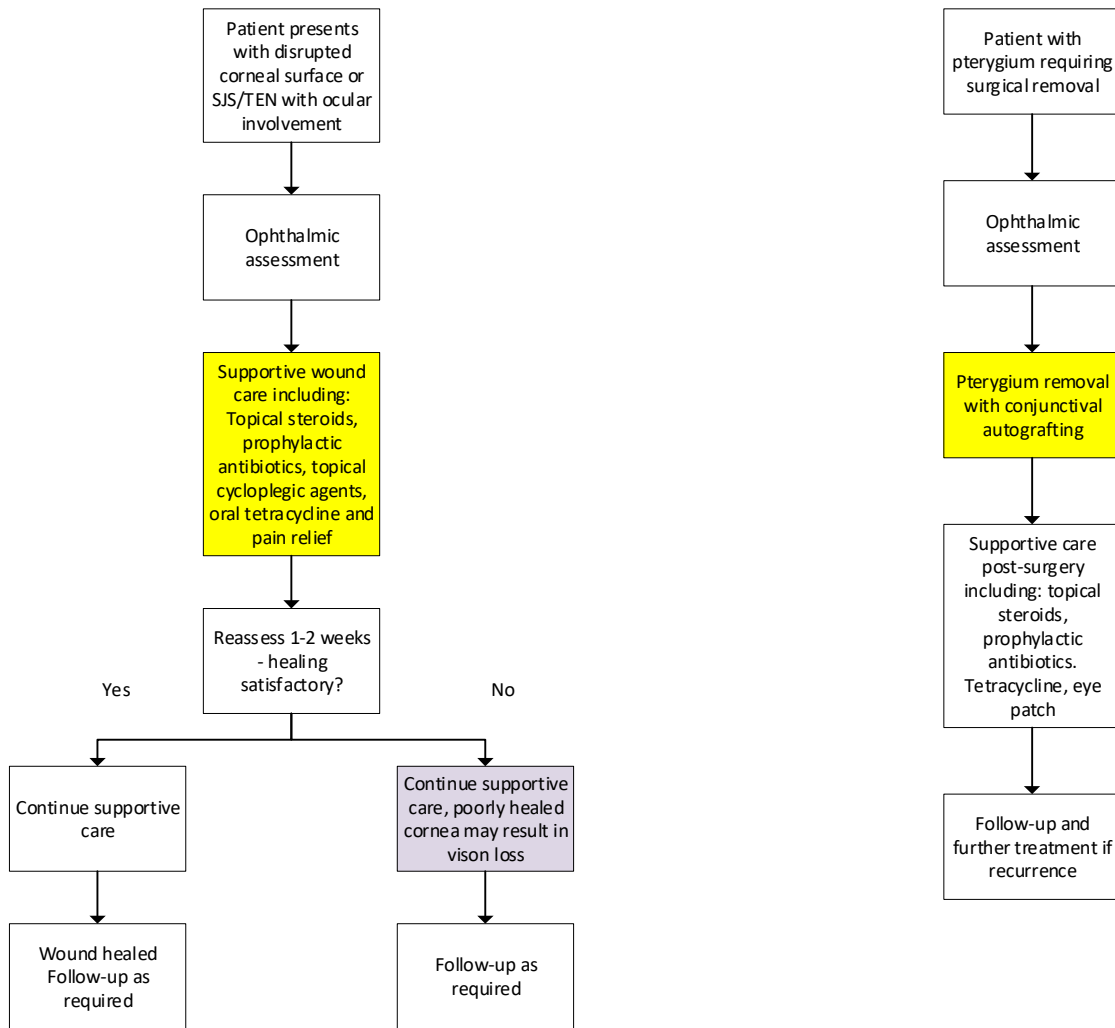
- Any subpopulations where amnion membrane may have different effectiveness or safety outcomes
- Differences in safety and effectiveness between amnion membrane preparations/formulations
- Variance in amnion membrane reapplication rates and the impact of this on economics via sensitivity analysis.

It is likely that for Populations 2 and 3 indirect or naïve comparisons will be required.

Current and proposed clinical management algorithms

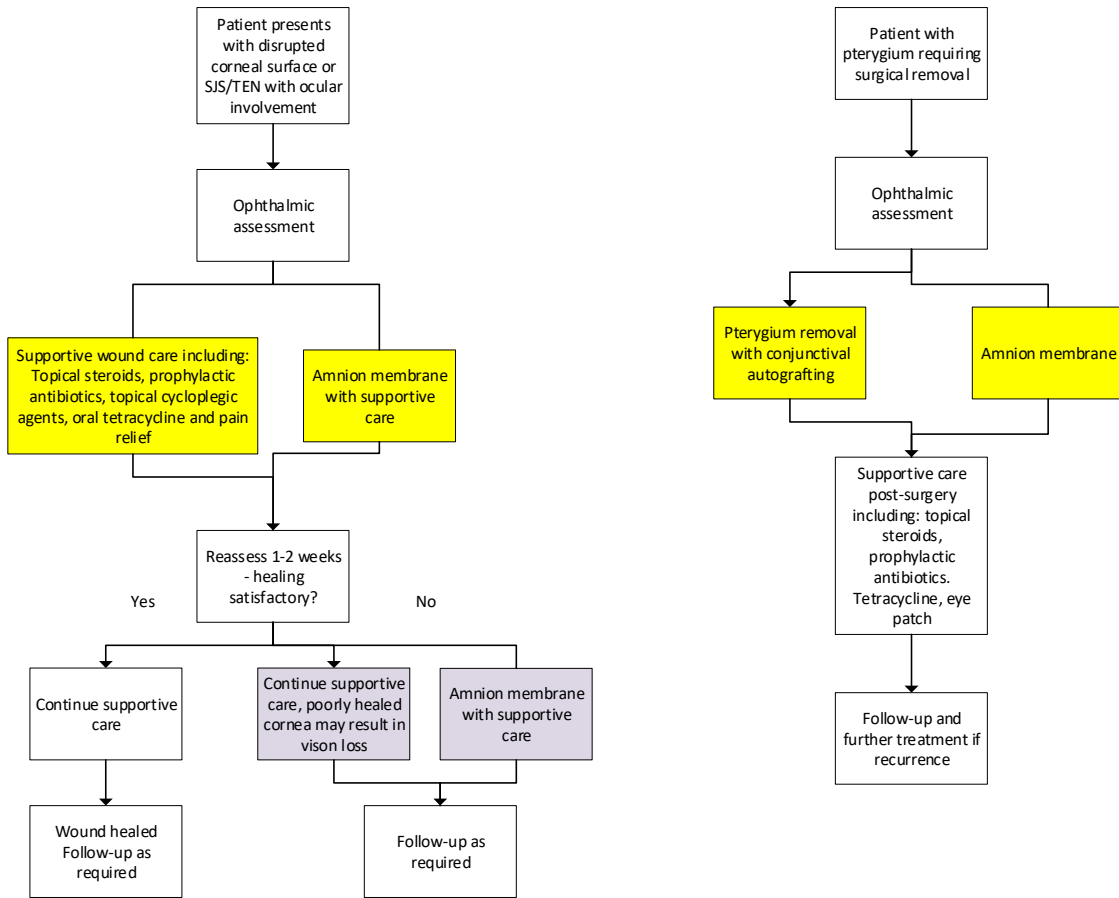
PASC confirmed the proposed clinical management algorithms for Population 1 and 2. However, the clinical algorithms for Population 3 will need to be updated to reflect the applicant's request to include three additional sub-groups within Population 3. The clinical algorithms below have been updated accordingly.

Current clinical management algorithm for Population 1



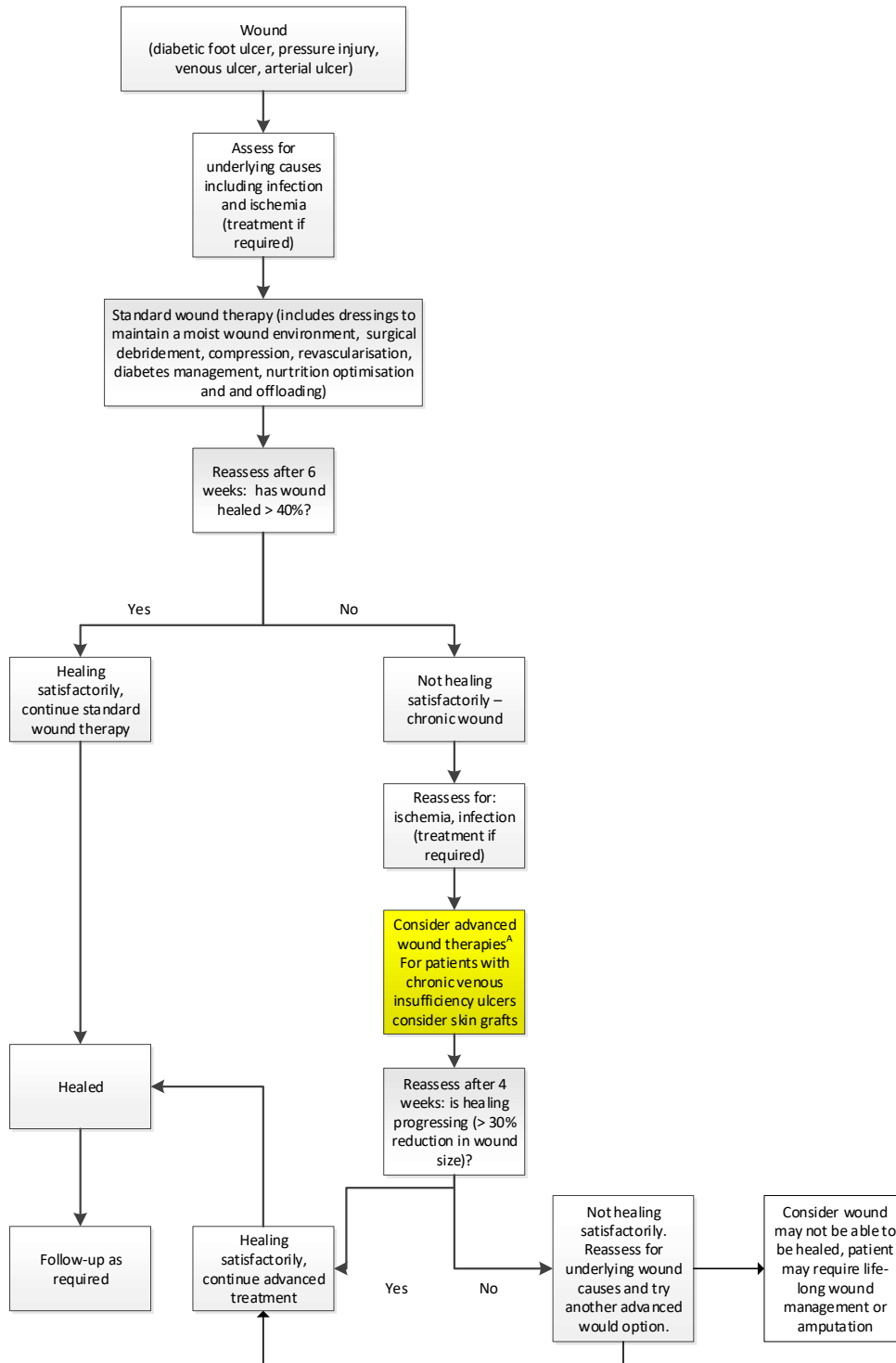
Source: produced by the Assessment Group based on published evidence and expert advice (Associate Professor of Ophthalmology, 2020, Bunya and Chang, 2019, Gupta et al., 2014, Hemmati and Colby, 2020, Hsu et al., 2012, Nouredin and Yeung, 2016, Sharma et al., 2016, Slentz and Hemmati, 2013, Wander and Kroger, 2020)

Proposed clinical management algorithm for Population 1



Source: produced by the Assessment Group based on published evidence and expert advice (Associate Professor of Ophthalmology, 2020, Bunya and Chang, 2019, Gupta et al., 2014, Hemmati and Colby, 2020, Hsu et al., 2012, Nouredin and Yeung, 2016, Sharma et al., 2016, Slenz and Hemmati, 2013, Wander and Kroger, 2020)

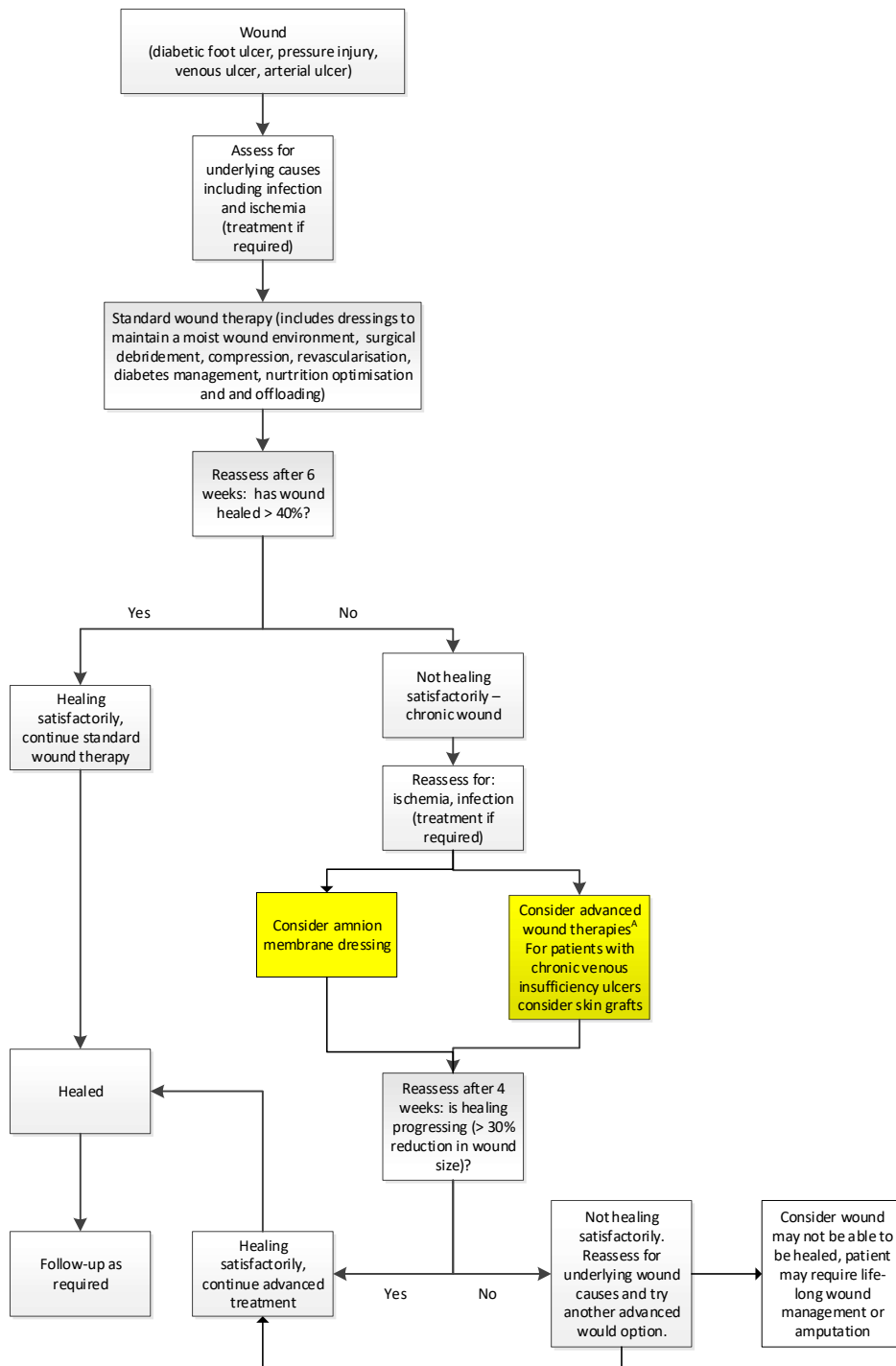
Current clinical management algorithm for Population 2



Source: Algorithm developed based on Expert Advice and published literature and Guidelines (DoH identified Expert, 2020, IWGDF, 2019, NICE, 2019b, NICE, 2019a, Plastic Surgeon, 2020, Professor of Vascular Surgery, 2020)

Note: A Expert advice is that UrgoStart dressings are used in Australia.

Proposed clinical management algorithm for Population 2

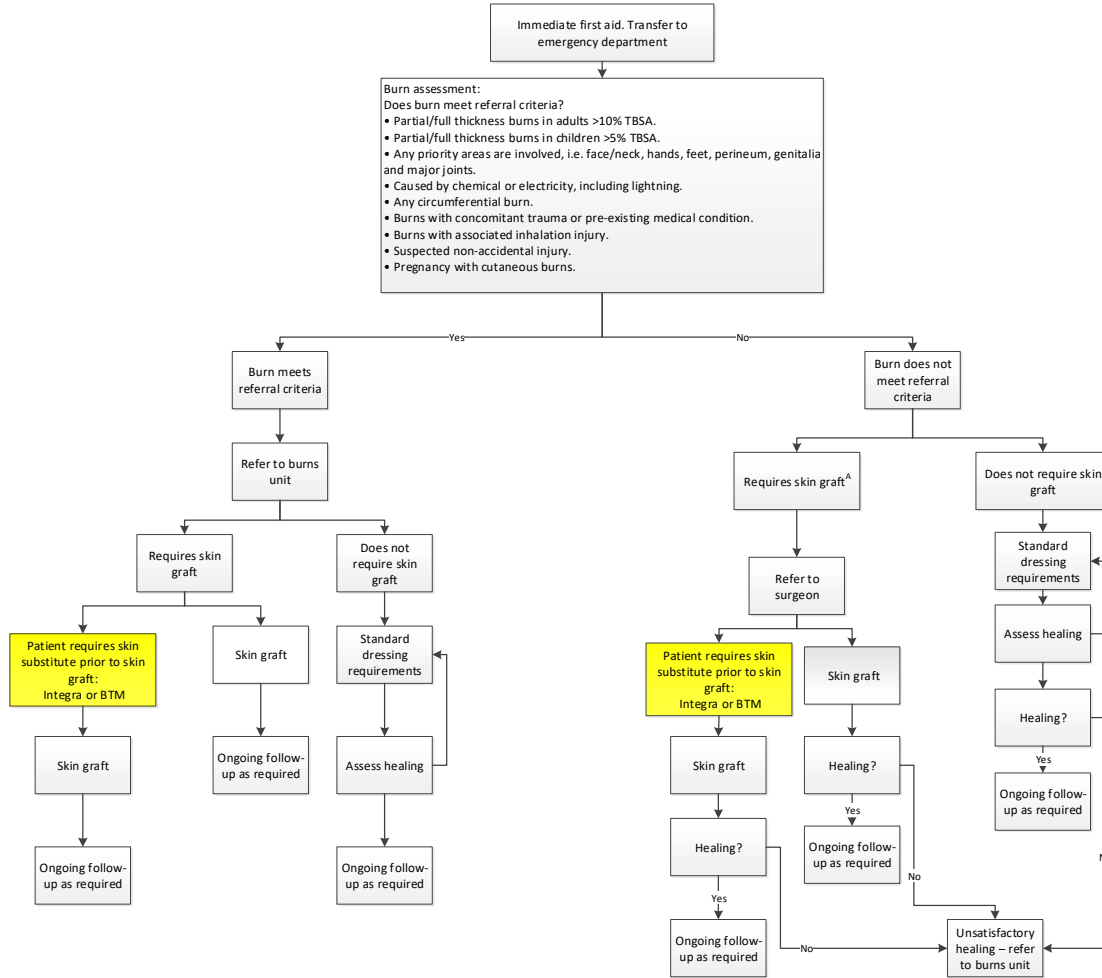


Source: Algorithm developed based on Expert Advice and published literature and Guidelines (DoH identified Expert, 2020, IWGDF, 2019, NICE, 2019b, NICE, 2019a, Plastic Surgeon, 2020, Professor of Vascular Surgery, 2020)

Note: A Expert advice is that UrgoStart dressings are used in Australia.

Current clinical management algorithm for Population 3a

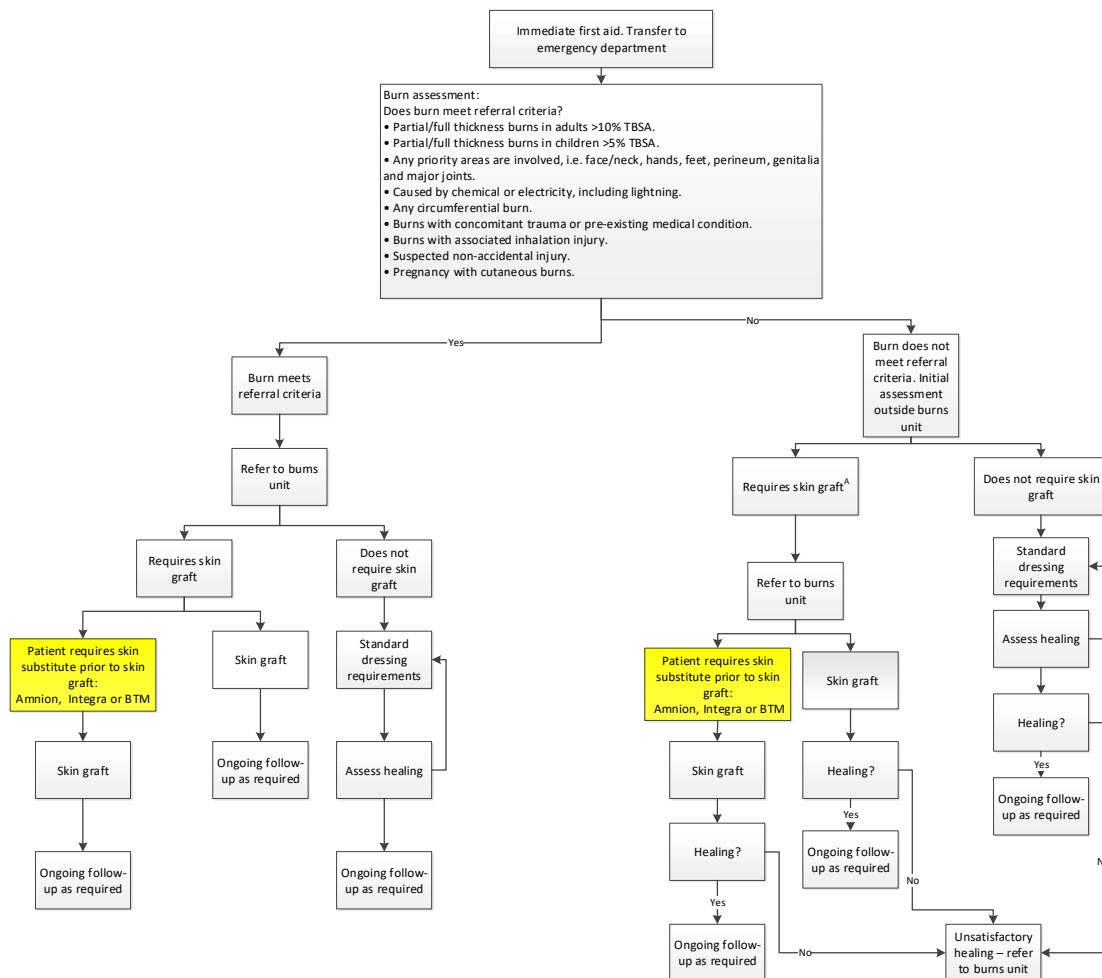
Burns where patients require a dermal substitute before skin grafting can take place



Source: developed by the Assessment group based on expert advice and published literature (BRANZ, 2019, Plastic and Reconstructive Surgeon, 2018, Plastic Surgeon, 2020, Victorian Adults Burns Service at the Alfred, 2018)
 Abbreviations: BTM = NovoSorbTM Biodegradable Temporising Matrix, TBSA = total body surface area
 Notes: A: Some small but deep partial and full thickness burns may require a skin graft.

Proposed clinical management algorithm for Population 3a

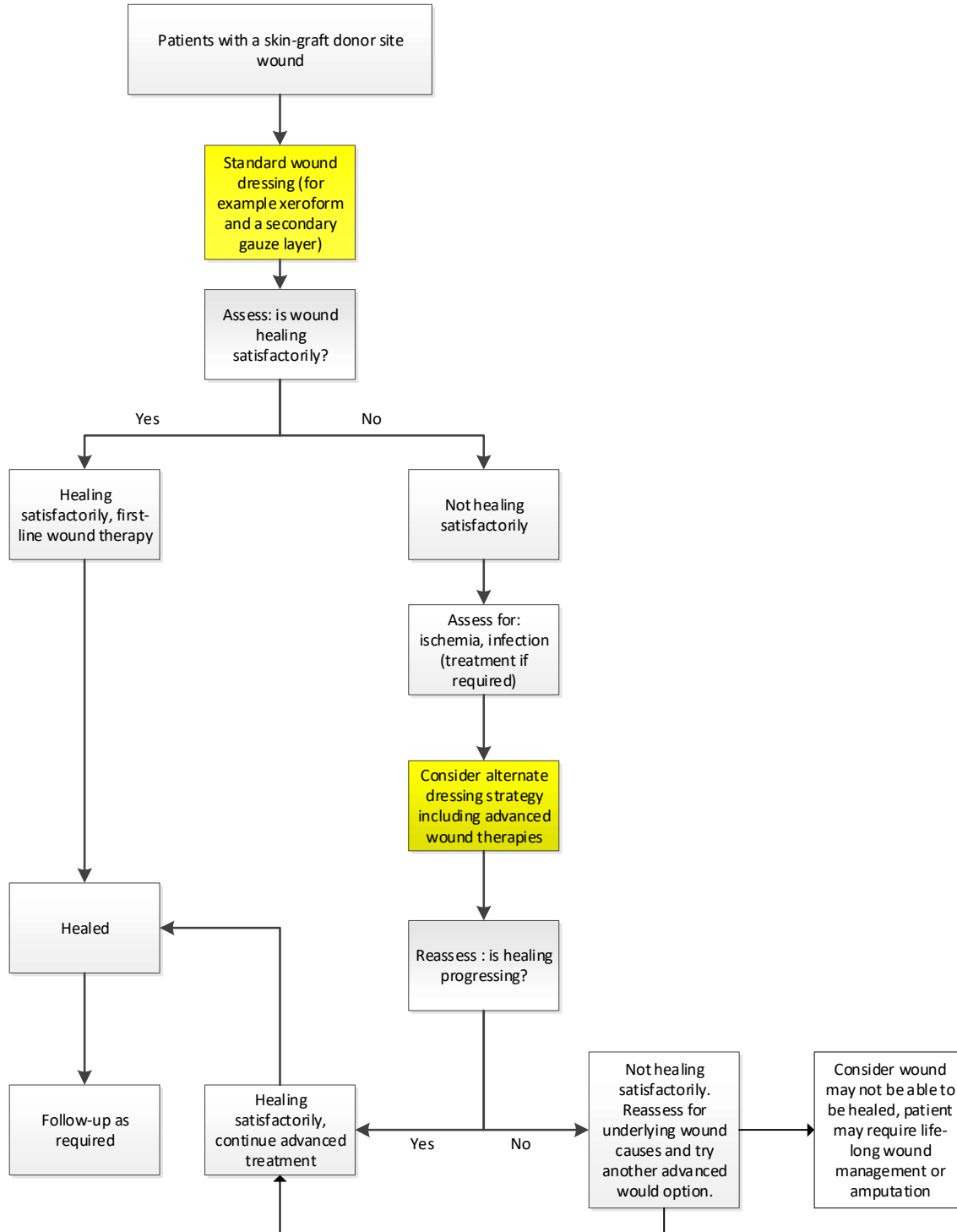
Burns where patients require a dermal substitute before skin grafting can take place



Source: developed by the Assessment group based on expert advice and published literature (BRANZ, 2019, Plastic and Reconstructive Surgeon, 2018, Plastic Surgeon, 2020, Victorian Adults Burns Service at the Alfred, 2018)
 Abbreviations: BTM = NovoSorbTM Biodegradable Temporising Matrix, TBSA = total body surface area
 Notes: A: Some small but deep partial and full thickness burns may require a skin graft.

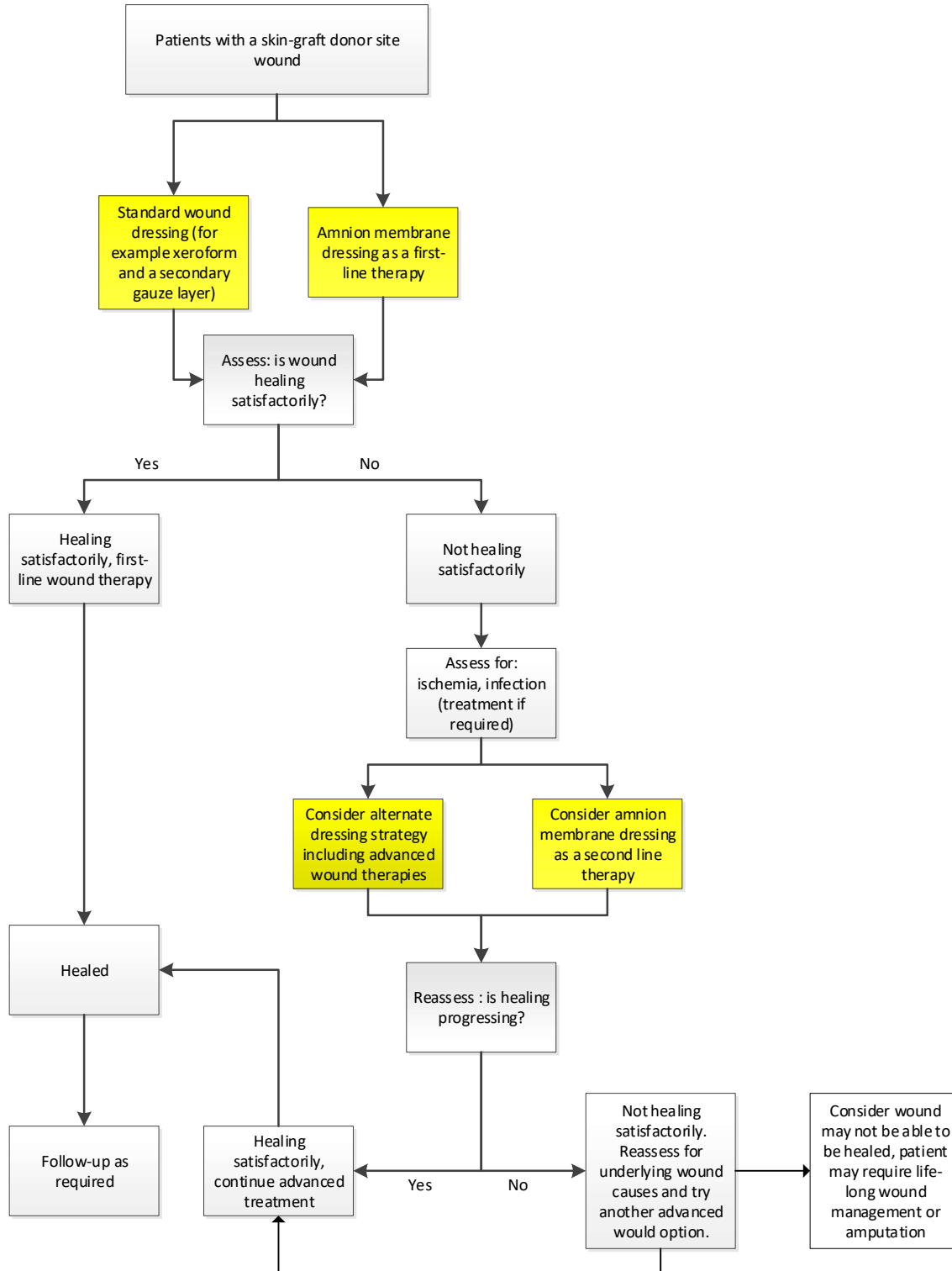
Current clinical management algorithm for Population 3b

Patients with a skin-graft donor site wound



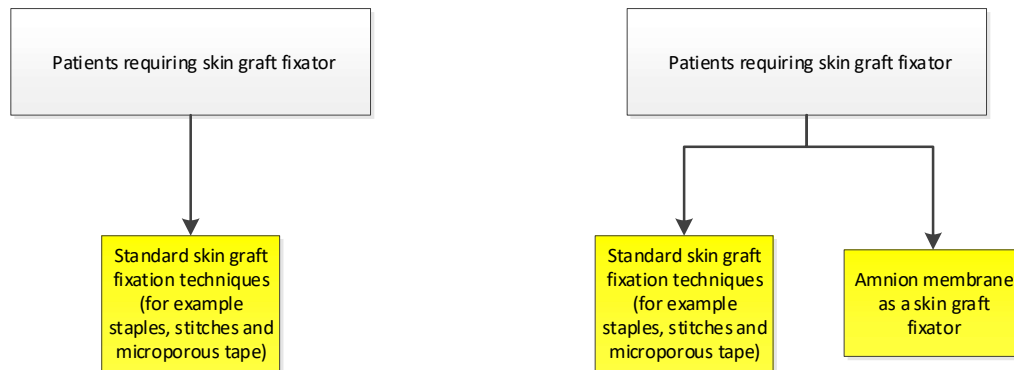
Proposed clinical management algorithm for Population 3b

Patients with a skin-graft donor site wound



Current and proposed clinical management algorithms for Population 3c

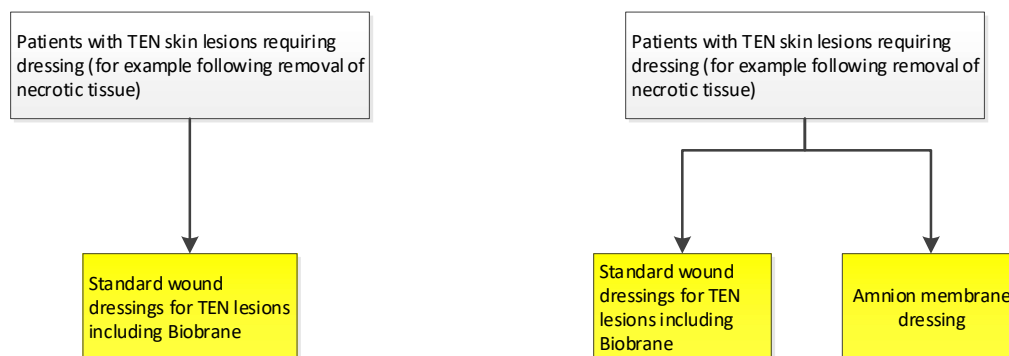
Patients requiring a skin graft fixator



The current algorithm is shown of the left hand side, the proposed algorithm is on the right

Current and proposed clinical management algorithms for Population 3d

Patients with TEN skin lesion requiring dressing



The current algorithm is shown of the left hand side, the proposed algorithm is on the right

Proposed economic evaluation

The Applicant claimed that cryopreserved amnion membrane is non-inferior to other forms of amnion membrane. No claim was presented for the comparators listed in this PICO. It is suggested that:

- In Population 1: Compared to standard care, amnion is superior for effectiveness and non-inferior for safety outcomes
- In Population 2: compared to advanced wound treatments (UrgoStart, split thickness skin grafts) amnion is superior for effectiveness and non-inferior for safety
- In Population 3: compared to dermal substitutes (BTM and Integra) amnion is non-inferior for safety and effectiveness

If a claim of superiority is supported a cost utility analysis is appropriate. If a claim of non-inferiority is supported, then a cost minimisation may be appropriate.

PASC confirmed that the proposed economic evaluation was appropriate.

Proposed MBS item descriptor and MBS fee

PASC noted that amnion membrane would be used under a range of existing MBS items, determined by the respective clinicians with varying costs for each item.

The Applicant proposed that amnion be listed on the Prostheses List, with a proposed benefit as outlined in Table 7.

Table 7 Proposed benefit for amnion products listed on Prosthesis List

Amnion size	Proposed benefit
5 cm diameter circle	\$578.57
5 x 10 cm	\$1,446.11
10 x 10 cm	\$2,892.87

Source: Application Form

The Applicant advised that costs outlined in Table 7 have been derived, based on a unit price of \$28.93 per cm². This is based on (Application Form) costs of:

- Amnion membrane retrieval consumables (\$9)
- Amnion membrane processing consumables (\$1,332)
- Pathology testing (\$4,767)
- Regulatory (\$1,347)
- Staff (\$2,316)
- Equipment depreciation and service (\$532)
- Courier (\$660).

The unit cost also includes an estimated 15% unutilised product, with \$2,923.32 for costs associated with tissue that is unable to be released, because of pathology results. A routine amnion membrane donation will produce a maximum of 24 x 20 cm² grafts in a range of sizes.

Consultation feedback

PASC noted the consultation feedback from the Royal Australian and New Zealand College of Ophthalmologists, which supported the application and noted that amnion membrane products would also be beneficial in the community setting to avoid hospital admission.

Next steps

PASC advised that, upon ratification of the post-PASC PICO, the application can proceed to the Evaluation Sub-Committee (ESC) stage of the MSAC process.

PASC noted the applicant has elected to progress its application as a DCAR (Department-contracted assessment report). PASC advised that the application should continue to progress as a single submission, ensuring subgroups analysis is carried out, where data permits.

References

- Abul, A., Karam, M. & Rahman, S. 2020. Human Amniotic Membrane: A New Option for Graft Donor Sites - Systematic Review and Meta-analysis. *Int Wound J*.
- Aihw. 2019. *Procedures Data Cubes, Procedures and healthcare interventions (ACHI 10th edition), Australia, 2017-18* [Online]. Australian Institute of Health and Welfare. Available: <https://www.aihw.gov.au/reports/hospitals/procedures-data-cubes/contents/data-cubes> [Accessed 16 March 2020].
- Aihw, Pointer, S. & Tovell, A. 2016. *Hospitalised burn injuries, Australia, 2013–14. Injury research and statistics series no. 102. Cat. no. INJCAT 178* [Online]. Canberra: Australian Institute of Health and Welfare. Available: <https://www.aihw.gov.au/getmedia/aa910281-ad80-4963-808e-c41bc7191039/20432.pdf.aspx?inline=true> [Accessed 16 March 2020].
- Alavi, A., Sibbald, R. G., Mayer, D., Goodman, L., Botros, M., Armstrong, D. G., Woo, K., Boeni, T., Ayello, E. A. & Kirsner, R. S. 2014. Diabetic foot ulcers: Part II. Management. *J Am Acad Dermatol*, 70, 21.e1-24; quiz 45-6.
- Alexiadou, K. & Doupis, J. 2012. Management of diabetic foot ulcers. *Diabetes therapy : research, treatment and education of diabetes and related disorders*, 3, 4-4.
- Associate Professor of Ophthalmology. 2020. RE: Personal Communication by an Associate Professor of Ophthalmology, phone call, 27 February 2020. Type to DUNCAN, J.
- Aushsi. 2017. *Issue Paper: Chronic Wounds* [Online]. Australian Centre For Health Services Innovation Available: <http://www.aushsi.org.au/wp-content/uploads/2017/08/Chronic-Wounds-Solutions-Forum-Issues-Paper-final.pdf> [Accessed 6 November 2018].
- Betterhealth. 2016. *Pterygium* [Online]. Victoria State Government. Available: <https://www.betterhealth.vic.gov.au/health/conditionsandtreatments/pterygium> [Accessed 16 March 2020].
- Branz. 2019. *Annual Report 1 July 2017 - 30 June 2018* [Online]. Burns Registry of Australia and New Zealand. Available: https://www.monash.edu/medicine/sphpm/branz/publications-and-reports#tabs_1410728-02 [Accessed 16 March 2020].
- Braza, M. & Fahrenkopf, M. 2019. *Split-Thickness Skin Grafts* [Online]. NCBI. Available: <https://www.ncbi.nlm.nih.gov/books/NBK551561/> [Accessed 16 March 2020].
- Broderick, C., Pagnamenta, F. & Forster, R. 2020. Dressings and topical agents for arterial leg ulcers. *Cochrane Database of Systematic Reviews*.
- Bunya, V. & Chang, V. 2019. *Ocular Surface Squamous neoplasia* [Online]. American Academy of Ophthalmology. Available: https://eyewiki.aaopt.org/Ocular_Surface_Squamous_neoplasia#General_treatment [Accessed 16 March 2020].
- Chan, L. & Cook, D. K. 2019. A 10-year retrospective cohort study of the management of toxic epidermal necrolysis and Stevens-Johnson syndrome in a New South Wales state referral hospital from 2006 to 2016. *Int J Dermatol*, 58, 1141-1147.
- Connolly, S. 2014. *Clinical Practice Guidelines: Burn Patient Management. ACI Statewide Burn Injury Service* [Online]. NSW Agency for Clinical Innovation,. Available: https://www.aci.health.nsw.gov.au/_data/assets/pdf_file/0009/250020/Burn_Patient_Management_-_Clinical_Practice_Guidelines.pdf [Accessed 1 November 2018].
- Dfa. 2020. *The serious impact of diabetic foot ulcers* [Online]. Diabetic Foot Australia. Available: <https://www.diabeticfootaustralia.org/for-patients/> [Accessed 16 March 2020].
- Diabetes Australia. 2020. *Diabetes in Australia* [Online]. Diabetes Australia,. Available: <https://www.diabetesaustralia.com.au/diabetes-in-australia> [Accessed 16 March 2020].
- Doh Identified Expert. 2020. RE: Expert advice obtained by the Department of Health from a Plastic Surgeon, email received 16 March 2020. Type to DUNCAN, J.
- Doh Medical Advisor. 2020a. RE: Personal Communication from DoH Medical Advisor, email received 11 March 2020. Type to DUNCAN, J.
- Doh Medical Advisor. 2020b. RE: Personal Communication from DoH Medical Advisor, teleconference 18 February 2020. Type to DUNCAN, J.

- Edmonds, M., Lazaro-Martinez, J. L., Alfayate-Garcia, J. M., Martini, J., Petit, J. M., Rayman, G., Lobmann, R., Uccioli, L., Sauvadet, A., Bohbot, S., Kerihuel, J. C. & Piaggese, A. 2018. Sucrose octasulfate dressing versus control dressing in patients with neuroischaemic diabetic foot ulcers (Explorer): an international, multicentre, double-blind, randomised, controlled trial. *Lancet Diabetes Endocrinol*, 6, 186-196.
- Eskandarlou, M., Azimi, M., Rabiee, S. & Seif Rabiee, M. A. 2016. The Healing Effect of Amniotic Membrane in Burn Patients. *World J Plast Surg*, 5, 39-44.
- Greenwood, J. E., Schmitt, B. J. & Wagstaff, M. J. D. 2018. Experience with a synthetic bilayer Biodegradable Temporising Matrix in significant burn injury. *Burns Open*, 2, 17-34.
- Gupta, S., Gupta, P. & Sayegh, R. 2014. *Healing a persistent corneal epithelial defect* [Online]. American Academy of Ophthalmology. Available: <https://www.aao.org/eyeNET/article/healing-persistent-corneal-epithelial-defect> [Accessed 16 March 2020].
- Hemmati, H. & Colby, K. 2020. *Treating Acute Chemical Injuries of the Cornea* [Online]. American Academy of Ophthalmology. Available: <https://www.aao.org/eyeNET/article/treating-acute-chemical-injuries-of-cornea> [Accessed 16 March 2020].
- Hsu, M., Jayaram, A., Verner, R., Lin, A. & Bouchard, C. 2012. Indications and outcomes of amniotic membrane transplantation in the management of acute stevens-johnson syndrome and toxic epidermal necrolysis: a case-control study. *Cornea*, 31, 1394-402.
- Ingraham, H. J., Donnenfeld, E. D. & Abramson, D. H. 2003. Effects of Ionizing Radiation on the Conjunctiva, Cornea, and Lens. In: SAGERMAN, R. H. & ALBERTI, W. E. (eds.) *Radiotherapy of Intraocular and Orbital Tumors*. Berlin, Heidelberg: Springer Berlin Heidelberg.
- Iwgdg. 2019. *IWGDG Practical guidelines on the prevention and management of diabetic foot disease* [Online]. International Working Group on the Diabetic Foot Available: <https://iwgdguidelines.org/wp-content/uploads/2019/05/IWGDG-Guidelines-2019.pdf> [Accessed 16 March 2020].
- Kamolz, L. P., Lumenta, D. B., Parvizi, D., Wiedner, M., Justich, I., Keck, M., Pfurtscheller, K. & Schintler, M. 2014. Skin graft fixation in severe burns: use of topical negative pressure. *Annals of burns and fire disasters*, 27, 141-145.
- Klama-Baryla, A., Labus, W., Kitala, D., Kraut, M., Nowak, M. & Kawecki, M. 2018. Experience in Using Fetal Membranes: The Present and New Perspectives. *Transplant Proc*, 50, 2188-2194.
- Klama-Baryla, A., Rojczyk, E., Kitala, D., Labus, W., Smetek, W., Wilemska-Kucharzewska, K. & Kucharzewski, M. 2020. Preparation of placental tissue transplants and their application in skin wound healing and chosen skin bullous diseases - Stevens-Johnson syndrome and toxic epidermal necrolysis treatment. *Int Wound J*, 17, 491-507.
- Lee, T. 2016. *The Ins and Outs of Corneal Wound Healing* [Online]. Review of Ophthalmology. Available: <https://www.reviewofoptometry.com/article/the-ins-and-outs-of-corneal-wound-healing> [Accessed 16 March 2020].
- Lohana, P., Hassan, S. & Watson, S. B. 2014. Integra™ in burns reconstruction: Our experience and report of an unusual immunological reaction. *Annals of burns and fire disasters*, 27, 17-21.
- Margolis, D. J., Berlin, J. A. & Strom, B. L. 1999. Risk factors associated with the failure of a venous leg ulcer to heal. *Arch Dermatol*, 135, 920-6.
- Mccosker, L., Tulleners, R., Cheng, Q., Rohmer, S., Pacella, T., Graves, N. & Pacella, R. 2019. Chronic wounds in Australia: A systematic review of key epidemiological and clinical parameters. *Int Wound J*, 16, 84-95.
- Mohammadi, A. A., Johari, H. G. & Eskandari, S. 2013. Effect of amniotic membrane on graft take in extremity burns. *Burns*, 39, 1137-41.
- Ngan, V., Oakley, A. & Dyall-Smith, D. 2016. *Stevens–Johnson syndrome / toxic epidermal necrolysis* [Online]. DermNetNZ. Available: <https://dermnetnz.org/topics/stevens-johnson-syndrome-toxic-epidermal-necrolysis/> [Accessed 23 March 2020].
- Nice. 2019a. *Diabetic foot problems: prevention and management. NICE guideline [NG19]* [Online]. National Institute of Health and Care Excellence. Available: <https://www.nice.org.uk/guidance/ng19/chapter/Recommendations#diabetic-foot-ulcer> [Accessed 16 March 2020].

- Nice. 2019b. *UrgoStart for treating diabetic foot ulcers and leg ulcers* [Online]. National Institute for Health and Care Excellence. Available: <https://www.nice.org.uk/guidance/mtg42> [Accessed 16 March 2020].
- Noureddin, G. S. & Yeung, S. N. 2016. The use of dry amniotic membrane in pterygium surgery. *Clin Ophthalmol*, 10, 705-12.
- Plastic and Reconstructive Surgeon. 2018. *RE: Personal Communication received from a Plastic and Reconstructive Surgeon, phonecall, 16 October 2018*. Type to DUNCAN, J.
- Plastic Surgeon. 2020. *RE: Personal Communication by a Plastic, Reconstructive and Hand Surgeon, email 12 March 2020*. Type to DUNCAN, J.
- Porter, A. & Pagan-Duran, B. 2020. *What is Photokeratitis — Including Snow Blindness?* [Online]. American Academy of Ophthalmology. Available: <https://www.aao.org/eye-health/diseases/photokeratitis-snow-blindness> [Accessed 23 March 2020].
- Professor of Vascular Surgery. 2020. *RE: Personal Communication by a Professor of Vascular Surgery, email received 12 March 2020*. Type to DUNCAN, J.
- Ramos, R. R. 2007. An easy and safe method of split-thickness skin graft fixation. *Burns*, 33, 1074-5.
- Romanelli, M., Serena, T., Kimble, R., Han, S., Kim, J., Cruz, J., Chong, S. & Al Assar, M. 2019. *Skin graft donor site management in the treatment of burns and hard-to-heal wounds* [Online]. Wounds International. Available: <https://www.woundsinternational.com/resources/details/wuwhs-position-document-skin-graft-donor-site-management-in-the-treatment-of-burns-and-hard-to-heal-wounds> [Accessed 23 March 2020].
- Sharma, N., Thenarasun, S. A., Kaur, M., Pushker, N., Khanna, N., Agarwal, T. & Vajpayee, R. B. 2016. Adjuvant Role of Amniotic Membrane Transplantation in Acute Ocular Stevens-Johnson Syndrome: A Randomized Control Trial. *Ophthalmology*, 123, 484-91.
- Sign. 2010. *Management of chronic venous leg ulcers* [Online]. Healthcare Improvement Scotland. Available: <https://www.sign.ac.uk/assets/sign120.pdf> [Accessed 16 March 2020].
- Slentz, D. & Hemmati, H. 2013. *Management of Stevens-Johnson Syndrome and Toxic Epidermal Necrolysis* [Online]. American Academy of Ophthalmology. Available: <https://www.aao.org/eyenet/article/management-of-stevensjohnson-syndrome-toxic-epider-2> [Accessed 16 March 2020].
- Solano, J. 2019. *Ocular Burns and Chemical Injuries* [Online]. Medscape. Available: <https://emedicine.medscape.com/article/798696-overview#a4> [Accessed 23 March 2020].
- Sussman, G. 2014. Ulcer dressings and management. *Australian Family Physician*, 43, 588-592.
- Thorton, J. & Gosman, A. 2004. *Skin grafts, skin substitutes and principles of flaps* [Online]. Selected Readings in Plastic Surgery. Available: <https://plasticsurgery.stanford.edu/content/dam/sm/plasticsurgery/documents/education/microsurgery/FlapsSelectedReadings.pdf> [Accessed 23 March 2020].
- Tran, A. K. & Sidhu, S. 2019. Stevens Johnson syndrome and toxic epidermal necrolysis - an Australian analysis of treatment outcomes and mortality. *J Dermatolog Treat*, 30, 718-723.
- Urgostart Manufacturer. 2020. *RE: Personal Communication from UrgoStart Manufacturer, email received 12 March 2020*. Type to DUNCAN, J.
- Vabs. 2019a. *Biobrane Management* [Online]. Victorian Adult Burns Service At The Alfred. Available: http://www.vicburns.org.au/wp-content/uploads/2019/04/Biobrane_Management_020419.pdf [Accessed 23 March 2020].
- Vabs. 2019b. *Donor Site Management* [Online]. Victorian Adult Burns Service At The Alfred. Available: http://www.vicburns.org.au/wp-content/uploads/2019/04/Donor_Site_Management_020419.pdf [Accessed 23 March 2020].
- Vei. 2020. *Pterygium* [Online]. Vision Eye Institute. [Accessed 16 March 2020].
- Victorian Adults Burns Service at the Alfred. 2018. *ANZBA Referral Criteria* [Online]. Alfred Health. Available: <http://www.vicburns.org.au/transfer-referral/anzba-referral-criteria/> [Accessed 1 November 2018].

- Vsgbi. 2020. *Arterial Ulcer* [Online]. The Vascular Society for Great Britain and Ireland. Available: https://www.vascularsociety.org.uk/patients/conditions/12/arterial_ulcer [Accessed 16 March 2020].
- Wagstaff, M. J. D., Schmitt, B. J., Coghlan, P., Finkemeyer, J. P., Caplash, Y. & Greenwood, J. E. 2015. A biodegradable polyurethane dermal matrix in reconstruction of free flap donor sites: a pilot study. *Eplasty*, 15, e13-e13.
- Wander, A. & Kroger, J. 2020. *Stevens-Johnson Syndrome* [Online]. American Academy of Ophthalmology. Available: https://eyewiki.org/Stevens-Johnson_Syndrome [Accessed 16 March 2020].