



Australian Government

Department of Health

Ratified PICO Confirmation

Application 1656

**Vertebral body tethering for adolescent
idiopathic scoliosis**

Summary of PICO/PPICO criteria to define the question(s) to be addressed in an Assessment Report to the Medical Services Advisory Committee (MSAC)

Component	Description
Patients	Patients with adolescent idiopathic scoliosis (AIS) aged 10 to 18 years old with Cobb angle $\geq 40^\circ$ and skeletally immature who failed standard care, including external bracing.
Intervention	Vertebral body tethering (VBT)
Comparator	Posterior spinal fusion (PSF)
Outcomes	<p><u>Safety outcomes</u></p> <ul style="list-style-type: none"> • Overall adverse events (AEs) rate • Serious AEs rate • Infection rate • Neurological complications rate • Device related events (e.g. loosening or migration of the implants) <p><u>Effectiveness outcomes</u></p> <ul style="list-style-type: none"> • Absolute change in major thoracic (MT) Cobb angle (degrees) • Proportional change in MT Cobb angle (correction, percentage) • Clinical success (as defined in each study) • Change in proximal (upper) thoracic curve (degrees) • Change in lumbar (thoracolumbar) curve (degrees) • Thoracic angle of trunk rotation (ATR, degrees) • Lumbar ATR (degrees) • Health-related quality of life (e.g. Scoliosis Research Society [SRS] 22-item or 24-item) • Pulmonary function <p><u>Healthcare system outcomes</u></p> <ul style="list-style-type: none"> • Surgical time • Length of hospital stay • Secondary surgeries, including VBT re-operation and spinal fusion (rates)

Overview

The applicant is requesting public funding under the Medicare Benefits Schedule (MBS). The applicant also noted that the proposed medical service, vertebral body tethering (VBT), is a new MBS item proposing a way of clinically delivering a new service to the MBS in terms of technology. The type of service is a therapeutic medical service, which relies on a prosthesis or device. The prosthesis or device the proposed medical service relies on is neither included in their application nor is being considered by the Prostheses List Advisory Committee (PLAC). The applicant also identified other sponsors (s) and / manufacture(s) with similar prostheses or device components in the Australian market to which their application is applicable. The sponsor and/or manufacturer is Globus Medical (REFLECT™). However, this device does not appear to be Australian Register of Therapeutic Goods (ARTG) listed.

Background on adolescent idiopathic scoliosis

Scoliosis is a form deformity of the spine where the spine appears as a lateral S- or C-shaped curvature in the coronal plane of more than 10°, as measured by the Cobb angle (the angle between the most tilted upper and lower vertebrae) (Fadzan & Bettany-Saltikov 2017). Tambe has estimated that 85% of scoliosis cases are adolescent idiopathic scoliosis (AIS), which refers to scoliosis in younger individuals aged 10-18 years old with unknown aetiology (Tambe et al. 2018). According to the data presented on Scoliosis Australia's website, the prevalence of AIS in Australia is 2 to 3 per cent for curves 10° or more and 0.1 per cent for curves >40° (Scoliosis Australia 2021). Approximately 10 per cent of AIS patients require treatment; however, only 0.1 per cent of patients require surgery (Horne, Flannery & Usman 2014). Scoliosis Australia also indicates that in very young children, infantile idiopathic scoliosis is more common in males than females; on reaching adolescence, the risk of curve progression is more common in females than males by the factor of 1:8-10.

However, there are differences between studies regarding the prevalence of AIS ratio of female to male. For example, Kamtsuiris found a prevalence ratio of female to male of 1.5:1, with a slight increase in females' proportion with age (Kamtsuiris et al. 2007). Further, the authors of another study reported a prevalence ratio of females to males of 2:1, rising to 3:1 in the age of 11–12 years (JS et al. 1985). Similarly, a further two studies have reported a ratio of 2:1 without differentiation of different age groups (Cilli et al. 2009; Nery et al. 2010).

Further, several studies reported greater Cobb angles in females than males (Asher 1980; JS et al. 1985; Lonstein et al. 1982; Rogala, Drummond & Gurr 1978; Suh et al. 2011). Table 1 summaries these study results, showing the correlation between Cobb angle and females' ratio against males. These results also show that scoliosis in females progress to a higher grade of severity. Indeed, the dominance of females in the AIS cohort can be as high as 10:1 for patients presenting with a Cobb angle greater than 30° (Lenke et al. 1992; SOUCACOS et al. 1997; Weinstein, Stuart L. et al. 2008).

Table 1: Prevalence and female to male ratio of different Cobb angles (Konieczny, Hüsseyin & Rüdiger 2013).

Cobb angle of curve	Prevalence (%)	Female: male ratio
11°–20°	1.5–3	1.4:1
21°–40°	0.2–0.5	2.8–5.4:1
>40°	0.04–0.3	7.2:1

Population

The applicant proposed population is: patients aged 10-18 years old suffering from AIS with a Cobb angle of $\geq 40^\circ$ and skeletally immature individuals whose growth plates are open, and significant axial growth is expected (Alharby 2010), with skeletal age assessed by a validated scale (e.g. Risser -1-5; Sanders: 1-8). PASC considered that skeletal maturity is a key determinant of patient eligibility for VBT.

PASC noted that skeletal maturity is assessed not only by age, but by bone age assessment on radiographs using validated methods such as the Sanders system (bone age assessed typically on a left hand and wrist X-ray) or Risser system (bone age assessed on a pelvis X-ray). PASC also noted the potential for discordance between the Sanders and Risser systems (Minkara et al. 2020).

PASC noted that this pre-operative assessment of the patient was important, as the applicant's expert advised that VBT revision rates were better in patients assessed with a Sanders classification of 3-4.

Various degrees of Cobb angle measured on radiograph determine the type of treatment required for the patient. A study has confirmed that bracing is appropriate for patients with a curve of 20° – 40° with high growth potential (Parr & Askin 2020). In contrast, surgery indications vary, depending on patient and curve factors; with surgery, including growth modulation, instrumentation without fusion and instrumentation with fusion, indicated when the curve is $>40^\circ$ (Parr & Askin 2020).

PASC noted that the Cobb angle ($\geq 40^\circ$) is an appropriate eligibility criterion but also that the Cobb angle ($<40^\circ$) was a measure of clinical success in the FDA study (see Outcomes section).

The applicant proposed VBT as a surgical option for patients with this degree of curvature, and the numbers of patients can be determined by the annual MBS claims for posterior spinal fusion (PSF) procedures for scoliosis claimed, as the applicant claims similar eligibilities will apply to VBT surgery as PSF. For example, in 2019, the number of scoliosis patients who required surgery in Australia was 397, Table 2. Furthermore, data released by the Australian Institute of Health and Welfare (2021) indicates the number of PSF procedures performed by public and private hospitals across Australia on patients aged 10 to 19 years old from 2018 to 2019 was 682 procedures (Table 5).

Table 2: Number of posterior spinal fusion (PSF) procedures for scoliosis cases

Descriptor	MBS Item Number	2015	2016	2017	2018	2019
SPINE, bone graft to, for a child or adolescent, associated with surgery for correction of scoliosis or kyphosis or both	50644	298	257	287	260	224
SCOLIOSIS OR KYPHOSIS, in a child or adolescent, treatment by segmental instrumentation and fusion of the spine	50608	229	189	224	201	171
Scoliosis or kyphosis, in a child or adolescent, spinal fusion for (without instrumentation)	50604	2	2	0	1	0
SCOLIOSIS, in a child or adolescent, congenital, resection and fusion of abnormal vertebra via an anterior or posterior approach	50640	3	3	1	2	2
Total		532	451	512	464	397

Source: Table developed by the applicant, and the content information has been obtained from Services Australia (http://medicarestatistics.humanservices.gov.au/statistics/mbs_item.jsp, accessed by applicant on 14 October 2020).

The number of MBS claims for PSF procedures between 2015 and 2019 range from 532 in 2015 to 397 in 2019 (**Error! Reference source not found.**). Further, the number of MBS claims for AIS

patients who underwent PSF surgery between July 2019 and June 2020 in Australia was 373 patients (Services Australia 2021). Although there is a slight variation in the number of patients who required PSF surgery, the numbers are stable with little variation across years. This indicates the continuity of the AIS among children/adolescents, necessitating surgical management.

PASC considered the applicant's projected utilisation of VBT procedures based on MBS utilisation (MBS items 50644, 50608, 50604 and 50640) an overestimation as MBS item 50644 is likely to be used in conjunction with MBS item 50608.

PASC advised that careful assessment of VBT uptake is required.

PASC also advised that in the assessment phase, the potential utilisation of VBT concerning the expansion of utilisation compared to PSF should be determined.

Rationale

There is significant evidence confirming that a Cobb angle greater than 40° is associated with a visible deformity that may result in emotional distress and diminished self-image (Farady 1983; Karol et al. 1993; Maruyama & Takeshita 2008). These authors also have reported that a Cobb angle greater than 40° may result in various cardiopulmonary health issues. As such, these patients require active intervention to either correct the curvature or prevent progression.

Bracing has been accepted as a general treatment modality for AIS with Cobb angle 20°-40° (Charles et al. 2006; Courvoisier et al. 2013; Nachemson et al. 1995). Braces have shown to effectively prevent further progression of scoliotic curves to 50° (Weinstein, Stuart L et al. 2013). However, several studies reported that bracing is most effective in patients with Cobb angle <40°, especially in those with limited growth potential (D'Amato, Griggs & McCoy 2001; Weinstein, Stuart L et al. 2013). Further there is a reported low effectiveness and success of bracing leading to curvature progression and complications associated with bracing interventions (Charles et al. 2006; Dolan & Weinstein 2007). Also, psychosocial and practical issues may add to problems associated with bracing (Merenda et al. 2011).

Therefore, surgery is a viable alternative for those who did not gain any health benefits from bracing. Spinal fusion, including PSF, is the major surgical procedure that is currently used to treat AIS patients who have a Cobb angle greater than 40°. However, this technique is not free of complications and major adverse events, including post-operative pulmonary complications (Yin et al. 2018), perioperative neurologic complication during PSF surgery (Thirumala et al. 2017), and loss of spinal flexibility due permanent vertebral fusion. Based on these factors, a recent advancement in the field of AIS has introduced VBT as a new surgical alternative to the clinical management of AIS, aiming at providing a better solution for the deformity, emotional distress and compromised pulmonary function that AIS patients may experience (Villamor et al. 2019). Therefore, surgery is recommended in patients with AIS to reduce the degree of Cobb angle and consequently prevent resultant life-threatening medical conditions, such as emotional distress and cardiopulmonary health issues.

PASC considered that MBS funding of VBT might result in patients seeking early access to corrective surgery; however, the Cobb angle restriction may address this concern.

Intervention

The proposed intervention is VBT.

Background on VBT

The VBT procedure is a type of surgery that aims at preserving spinal mobility by exploiting the Heuter-Volkman principle in patients with scoliosis who have not reached skeletal maturity (Miyajji et al. 2020). The Heuter-Volkman Law proposes that the growth of spine is decreased by applying mechanical compressions and accelerated by reduced loading (Stokes, I 2002). This principle has been demonstrated from a combination of clinical observation and animal experiments in which the growth plates of growing animals have been loaded. The VBT procedure has been shown effective in experimental studies (Stokes, IAF et al. 1998; Stokes, IAF et al. 1996); however, little has been published about its efficacy in treating human adolescent idiopathic scoliosis. The first case report came from Crawford and Lenke in 2010 when they presented a thoracic curve tethering with clear evidence of growth modulation in an 8-year-old male (Crawford & Lenke 2010). Following this case report, several surgeons performed the procedure “off-label” resulting in two peer-reviewed publications (Samdani, Amer F. et al. 2014; Samdani, Amer F et al. 2015). The former performed the procedure on 11 patients with an average age of 12 ± 3 years and 2 years of follow-up; the preoperative curve of $44\pm 9^\circ$ was improved to $14\pm 12^\circ$ with an 18 per cent revision rate. The latter recruited 32 patients who underwent thoracic VBT with a minimum one-year follow-up. These are followed by several other observational studies (Cobetto, Aubin & Parent 2018; Newton et al. 2018; Pehlivanoglu et al. 2020).

Indications for use

The applicant has indicated that the VBT procedure will be a suitable option for the treatment of AIS, as it is a minimally invasive procedure. Due to the novelty of the procedure, data showing the effectiveness of VBT is limited. Based on their data generated from a study that included 29 patients with AIS, Hoernschemeyer et al. (2020) concluded that the best candidates for VBT include patients with a Cobb angle between 45° and 70° . These authors have also reported that the VBT procedure showed a 74% success rate. Further, they also noted that PSF was avoided in 93% of patients. However, there were several complications associated with the procedure, including broken tethers and overcorrections.

The U.S Food and Drug Administration (FDA) recommends VBT procedure for patients suffering from AIS aged 10-18 years old with a Cobb angle $\geq 30^\circ$ to 65° (FDA 2019). The FDA also confirmed that VBT procedure can be indicated for skeletally immature patients requiring surgical treatment to obtain and maintain correction of progressive idiopathic scoliosis. On the other hand, throughout the literature, there are various Cobb angle eligibilities for VBT procedure. For example, VBT was performed on patients with an average Cobb angle $< 40^\circ$, ranging from 22° through to 59° (Alanay et al. 2020; Hoernschemeyer et al. 2020; Samdani, Amer F et al. 2015; Wong et al. 2019). In contrast, other reports indicate that patients had to have a Cobb angle greater than 40° to be eligible for VBT (Ergene 2019; Jobidon-Lavergne et al. 2019; Pehlivanoglu et al. 2020).

Procedure

The VBT procedure is a thoracoscopic, minimally invasive procedure in which screws are placed into the vertebral bodies on the convex side of the coronal deformity (Hoernschemeyer et al. 2020). The screws placed into the vertebral bodies are then connected by flexible cable made of synthetic polymer. The applicant cited a study by Newton et al. (2020), claiming that the VBT procedure typically takes 3-3.5 hours and performed by an orthopaedic/spinal surgeon, under fluoroscopic

guidance. An assisting general (access) surgeon may be required for anterior exposure of the spine. The procedure time has been confirmed through the cited study, and the mean surgical time was (194 ± 30 min) (Newton 2020). Another study has reported that the average surgical duration to perform VBT was estimated to be 276 ± 162 min (Baroncini, Trobisch & Migliorini 2021). This study consisted of two 20-patient cohorts; overall surgical duration was notably shorter (163 ± 57.7 min) in the second cohort of patients (n=20) compared to the first cohort (390 ± 267.3 min) of patients (n=20). This difference between the two cohorts in overall surgical duration may reflect a learning curve effect due to the performing surgeon's limited previous experience with anterior approaches to the thoracic and lumbar spine, as noted in the article's methods section. Further, the average and range of surgical times are presented in

Table 3. The range in surgical duration may reflect the number of vertebrae tethered.

Table 3: Average and range of overall surgical duration in seven studies

Study References	Average surgical duration (min)	Range Surgical duration (min)
(Baroncini, Trobisch & Migliorini 2021)	1 st cohort (390 ± 267.3) 2 nd cohort (163 ± 57.7)	Not reported
(Alanay et al. 2020)	157.75	120 - 345
(Ergene 2019)	290	120 - 660
(Miyanji et al. 2020)	221.9	110 - 505
(Pehlivanoglu et al. 2020)	196 ± 44	185-268
(Samdani, Amer F. et al. 2014)	348	332-362
(Samdani, Amer F et al. 2015)	286.2	262.7-324.5

The procedure starts with administering general anaesthesia to the patient and followed by a small incision in the side of the chest to access the spine. The orthopaedic/spinal surgeon then places titanium screws into the convex side of the vertebrae with the aid of a fibre-optic video camera (Newton 2020). This is followed by connecting (tethering) the screws by a flexible cable made of synthetic polymer, which is secured alongside of the patient's vertebrae (Figure 1). The tether is then pulled taut, which guides the patient's future spinal growth and delay or eliminate the need for a definitive fusion (Guille, D'Andrea & Betz 2007). The tether, in most cases, does not need to be removed and can remain in the patient's spine throughout their lifetime. However, it has been reported in several studies that the tether can break resulting in VBT re-operation. Further, the tether had to be adjusted when overcorrections occurred (Hoernschemeyer et al. 2020; Newton et al. 2020; Samdani, Amer F. et al. 2014; Samdani, Amer F et al. 2015).

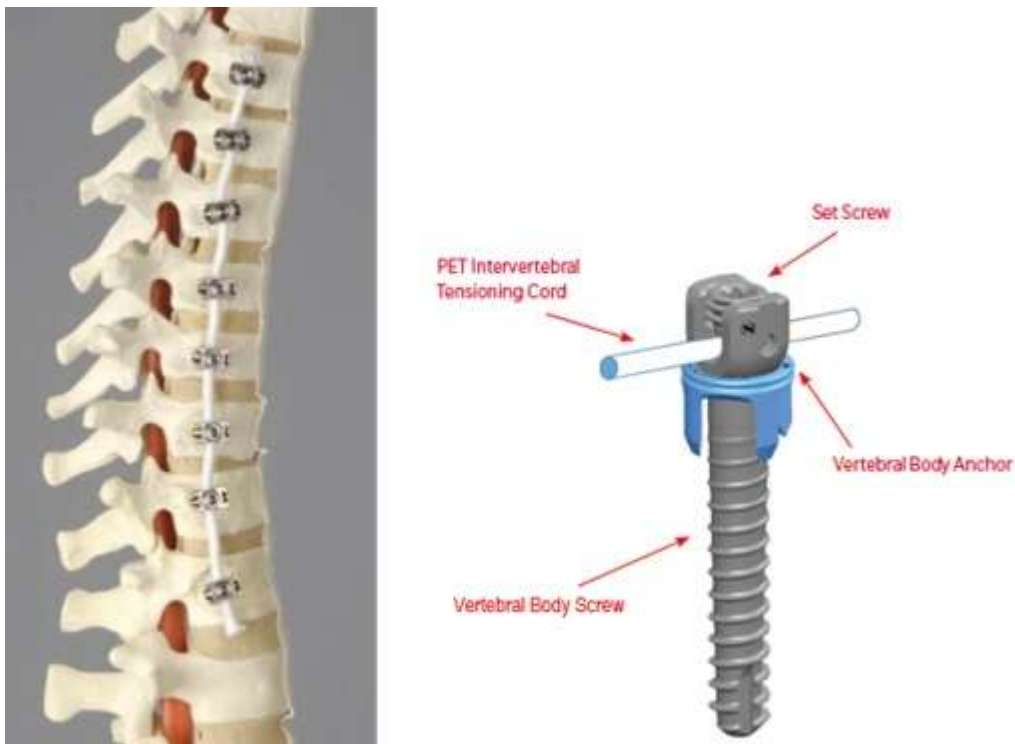


Figure 1: Vertebral body tethering (right: shows how the tether is implemented) and (left: shows tethered vertebrae) (FDA 2019)

The applicant provided the proposed costing information for the equipment used in the procedure (Application form, p20), including vertebral body screws (assuming on an average, 7 vertebrae levels are tethered based on the clinical evidence provided in the application form), anchor and cord. *PASC noted the high cost of the equipment used in the procedure (cord, anchor and 7 screws on average) and that the tether is currently not listed on the Prostheses List (PL). PASC considered that PL listing will be required for private health insurance reimbursement of the device.*

Rationale

Further to its minimal invasiveness, the VBT procedure aims to provide a greater range of motion to the patient following surgery than the current surgical approaches to AIS clinical management. The applicant also pointed out that the recovery after VBT is shorter than the most frequently used current surgical procedures, including PSF. This has been confirmed through literature that compared VBT to PSF. Further, VBT has the potential to offer skeletally immature patient's substantial correction of their deformity with greater spinal flexibility, allowing continued growth (Newton et al. 2018; Samdani, Amer F et al. 2015). In addition to these benefits, patients undergoing VBT procedure may have lower estimated blood loss and shorter operating time in comparison to PSF (Newton et al. 2018).

Contraindication

The VBT system should not be implanted in patients with following criteria (FDA 2019):

- presence of any kind of systemic or local infections
- presence of skin compromise at the surgery site
- prior spinal injury at the level(s) to be treated
- patients with poor bone quality defined as a T-score -1.5 or less
- patients reached skeletal maturity
- medical or surgical conditions, including coagulation disorders, allergies to the implant materials, and patient unwillingness or inability to cooperate with post-operative care instructions.

To date, there is no other agency review for VBT procedure. However, the National Institute for Health and Care Excellence (NICE) gave the procedure a number (1557 / 1) and the status is set as being 'monitored' (National Institute for Health and Care Excellence 2021). NICE indicated that they are awaiting the publication of (further) literature for this procedure.

PASC noted that VBT is a novel procedure with the FDA approval (Humanitarian Use Device (HUD) Designation) based on Level IV evidence (an investigational device). PASC also noted that the United Kingdom National Health Service (NHS) England 2018 review of VBT for the treatment of idiopathic scoliosis concluded that further research is needed to confirm the safety, patient acceptability and effectiveness of VBT. In addition, this review advised that further studies should include long-term follow up (beyond skeletal maturity) and outcomes relating to pulmonary function, gait analysis, range of motion and patient experience.

Comparator

The applicant considers that VBT will replace spinal fusion (typically done with a posterior approach, e.g. PSF). However, reports from several studies show that a percentage of patients that undergo the VBT procedure may require PSF surgery. For example, in a clinical study, three out of nine VBT revision cases were required to undergo PSF surgery (Newton et al. 2020). Further, another study has also shown that two out of six surgical revision cases required PSF after they were treated with VBT (Hoernschemeyer et al. 2020).

Spinal fusion

Spinal fusion is the current approach for the treatment and management of AIS with a Cobb angle of $\geq 40^\circ$. A bone graft taken from the patient, bone bank or an artificial substitute is utilised to promote fusion between two vertebrae, improve stability, correct a deformity or reduce pain (Tarpada, Morris & Burton 2017). The most common approach of spinal fusion Table 2, which involves metal screws, plates, and rods, is generally performed using the posterior approach. After general anaesthesia, an incision at the back of the spine is made, and pedicle screws are utilised, placed above and below the fused vertebrae, to provide extra support and strength to the purported spinal fusion. The pedicle screws are connected by the rod to prevent movement and promote healing. The screws and rod can be removed after the surgery if they cause pain and discomfort (Deyo, Nachemson & Mirza 2004).

PASC agreed that PSF is the appropriate comparator for VBT, with VBT hypothesised as a direct replacement.

Outcomes

Safety outcomes

- Potential device or procedure-related adverse events: Like most spinal surgical procedures, VBT may have several device or procedure-related adverse events. The following is the list of potential procedure-related adverse events documented by the FDA (FDA 2019):
 - Overcorrection of the coronal deformity, potentially requiring revision or removal of implants
 - Inadequate curve correction
 - Loss of curve correction
 - Development of new curves above and/or below the instrumented levels
 - Trunk imbalance
 - Worsening of existing deformities in non-tethered spine segments
 - Unintended spontaneous fusion at the instrumented levels
 - Pulmonary complications including atelectasis, pneumonia or adverse events related to temporary single lung ventilation
 - Anaesthesia complications
 - Wound infection, superficial or deep
 - Wound dehiscence
 - Damage to surrounding organs and structures including blood vessels, spinal cord, nerves, lungs, or vertebral bodies
 - Vascular complications including bleeding, haemorrhage, or vascular damage leading to anaemia or requiring blood transfusion
 - Neurologic complications including damage to neurological structures, cerebrospinal fluid leakage, or meningocele
 - Problems during device placement including anatomic/technical difficulty and device-sizing issues
 - Loosening or migration of the implants
 - Bending, fracturing, fraying, kinking, loosening, bending, or breaking of any or all implant components
 - Fretting and crevice corrosion at interfaces between components
 - Pain, discomfort, or abnormal sensations due to device presence
 - Material sensitivity reactions and/or particulate wear debris

Some of the adverse events above have been reported in clinical studies that included VBT as an intervention. For example, in a study that recruited five patients, which subsequently underwent the VBT procedure, there were 20 adverse events, of which 16 were mild, and four were moderate in severity. The four moderate events of pneumonia, distal decompensation, curve progression, and overcorrection occurred in three patients, two of whom required fusion (Wong et al. 2019). Further, another study has shown that out of the 31 recruited patients, six patients experienced overcorrection, four exhibited pulmonary and six mechanical complications, including (upper instrumented vertebrae loosening, pull-out, migration, lower instrumented vertebrae pull-out, loss of previously achieved correction, and tether breakage, one each) (Alanay et al. 2020). Further, the rate of thoracic complication was 9.2 per cent, and 30-day readmission was 1.8 per cent in a study of 56 patients undergoing a VBT procedure (Ergene 2019). Additionally, in a comparison study between VBT and PSF procedures, it was noted that out of 23 patients, there were nine revision procedures in the VBT cohorts and 12 (52%) patients experienced broken tethers, of which four patients went

through revision procedures (Newton et al. 2020). These authors also indicated that revisions occurred at a mean postoperative time of 2.3 years (range, 1.2 to 3.7 years). Further, both procedures resulted in postoperative correction; however, 2-year correction was better maintained in the PSF group (

Table 4).

- Systemic adverse events: FDA has also outlined the following systemic adverse events that may associated with VBT procedure:
 - Deep vein thrombosis
 - Pulmonary embolism
 - Atelectasis, pneumonia
 - Cardiac AEs
 - Dysphagia
 - Dysphonia
 - Gastrointestinal (ileus, ulceration, bleeding, malnutrition)
 - Foreign body reaction
 - Pressure sores
 - Genitourinary (infection, urinary retention)
 - Infection (systemic)
 - Hematologic
 - Endocrine/metabolic
 - Hepatobiliary
 - Immunologic
 - Gynaecologic
 - Ophthalmologic
 - Psychological
 - Surgical procedure: non-spinal
 - Wound infection: non-spinal

PASC noted the potential of adverse events related to the device, including under- and overcorrection of the curve, and device failure which may require revision surgery.

PASC noted that complications associated with VBT, including over- and under-corrections, failure to correct the curve and device failure. PASC noted that after VBT complications, PSF may be undertaken in 25 - 50% of cases.

Effectiveness outcomes

- Absolute change in major thoracic (MT) Cobb angle (degrees)
- Proportional change in MT Cobb angle (correction, percentage)
- Clinical success. This has been described differently throughout the literature. Definitions of clinical success include:
 - having a curve of $<35^{\circ}$ and no PSF performed or indicated at the final follow-up (Miyanji et al. 2020; Newton et al. 2020)
 - Cobb angle of less than or equal to 40° at 24 months following treatment with The Tether™ – Vertebral Body Tethering System (FDA 2019)
 - and Cobb angles of less than 30° (Hoernschemeyer et al. 2020).
- Change in proximal (upper) thoracic curve (degrees)

- Change in lumbar (thoracolumbar) curve (degrees)
- Thoracic angle of trunk rotation (ATR, degrees)
- Lumbar ATR (degrees)
- Health-related quality of life- patient reported outcomes using a standardised tool (e.g. EuroQol- 5 dimension [EQ-5D] or Short Form Survey [SF-36]) or disease specific tool (e.g. Scoliosis Research Society [SRS] 22-item or 24-item)
- Pulmonary function (e.g. forced vital capacity [FVC] and forced expiratory volume [FEV])

The outcome measurements (radiographic, clinical and patient-reported outcomes) above have been used in full or partially in many clinical studies that employed VBT as an intervention (Ergene 2019; Hoernschemeyer et al. 2020; Miyanji et al. 2020; Newton et al. 2020; Pehlivanoglu et al. 2020; Samdani, Amer F. et al. 2014; Samdani, Amer F et al. 2015; Wong et al. 2019). In addition to the above effectiveness outcomes, several studies have also utilised other outcome measurements, including lumbar lordosis and kyphosis as well as coronal, sagittal, and shoulder balances (Pehlivanoglu et al. 2020; Samdani, Amer F. et al. 2014; Samdani, Amer F et al. 2015).

PASC noted that changes of the Cobb angle, assessed on radiograph, was the primary outcome listed in the application.

PASC noted that the Cobb angle is the accepted standard for proof of surgical correction but considered that radiographic outcomes are surrogate outcomes and queried if these had been validated to predict patient-relevant outcomes. PASC considered this issue to be important and advised that patient-relevant outcomes should be clearly described and considered in the assessment phase.

PASC considered that the disease specific Scoliosis Research Society [SRS] 22-item or 24-item patient questionnaire would be appropriate to capture health related quality of life (HrQoL).

PASC noted the feedback from the Spine Society of Australia that long-term follow-up patient-related outcomes for 2-5 years until skeletal maturity, with 5-yr review is required.

Healthcare resources

- Surgical time
- Length of hospital stay
- Secondary surgeries, including VBT re-operation and spinal fusion (rates)

Surgical time has been reported as a healthcare outcome measurement of VBT procedure in several studies (Alanay et al. 2020; Ergene 2019; Miyanji et al. 2020; Newton et al. 2020; Pehlivanoglu et al. 2020). However, few studies have reported the length of hospital stay (Ergene 2019; Newton et al. 2020). Due to not achieving the anticipated surgical goal, some patients need to be re-operated, including VBT re-operation. Therefore, many studies have reported secondary surgeries as an outcome measurement (Hoernschemeyer et al. 2020; Newton et al. 2020; Pehlivanoglu et al. 2020; Samdani, Amer F. et al. 2014).

Whether less invasive procedures, such as VBT increase the number of surgeries, should be addressed at the assessment phase.

Current and proposed clinical management algorithm for identified population

Current clinical management

Current clinical management (Scoliosis Australia 2021) pathway to assess patients eligibility for VBT surgery is as follows:

- Self-detection (outward signs)
- Forward standing test
- X-ray examination
- External bracing (where Cobb angle $\geq 30^\circ$)
- Surgery (on failure of bracing and where the Cobb angle $\geq 40^\circ$). Currently these patients undergo spinal fusion procedures, as depicted below (PSF) in management algorithm.

Diagnosis & Screening of Scoliosis

- The most frequent screening test for scoliosis is the Adams test: the patient is examined from the rear and asked to bend forward until the spine is horizontal, one side of the back may appear higher than the other.
- Physical examination specific for scoliosis performed by physicians: the examination is conducted with the patient standing in a relaxed position with their arms at their sides. The physician will view the patient from behind, looking for curvature of the spine, shoulder blade asymmetry, waistline asymmetry, and trunk shift.
- Radiography imaging: physicians usually obtain initial radiographs of the spine viewed from the back and the side to see the entire spine from the neck to the pelvis. If scoliosis is present, the physician will measure the radiographs and provide the patient with a numerical value, in degrees, to help describe their scoliosis. Depending on the severity of the case and need for specialist clinical management, the patients will be referred to orthopaedic specialists by the physician.

Current and proposed clinical management algorithm

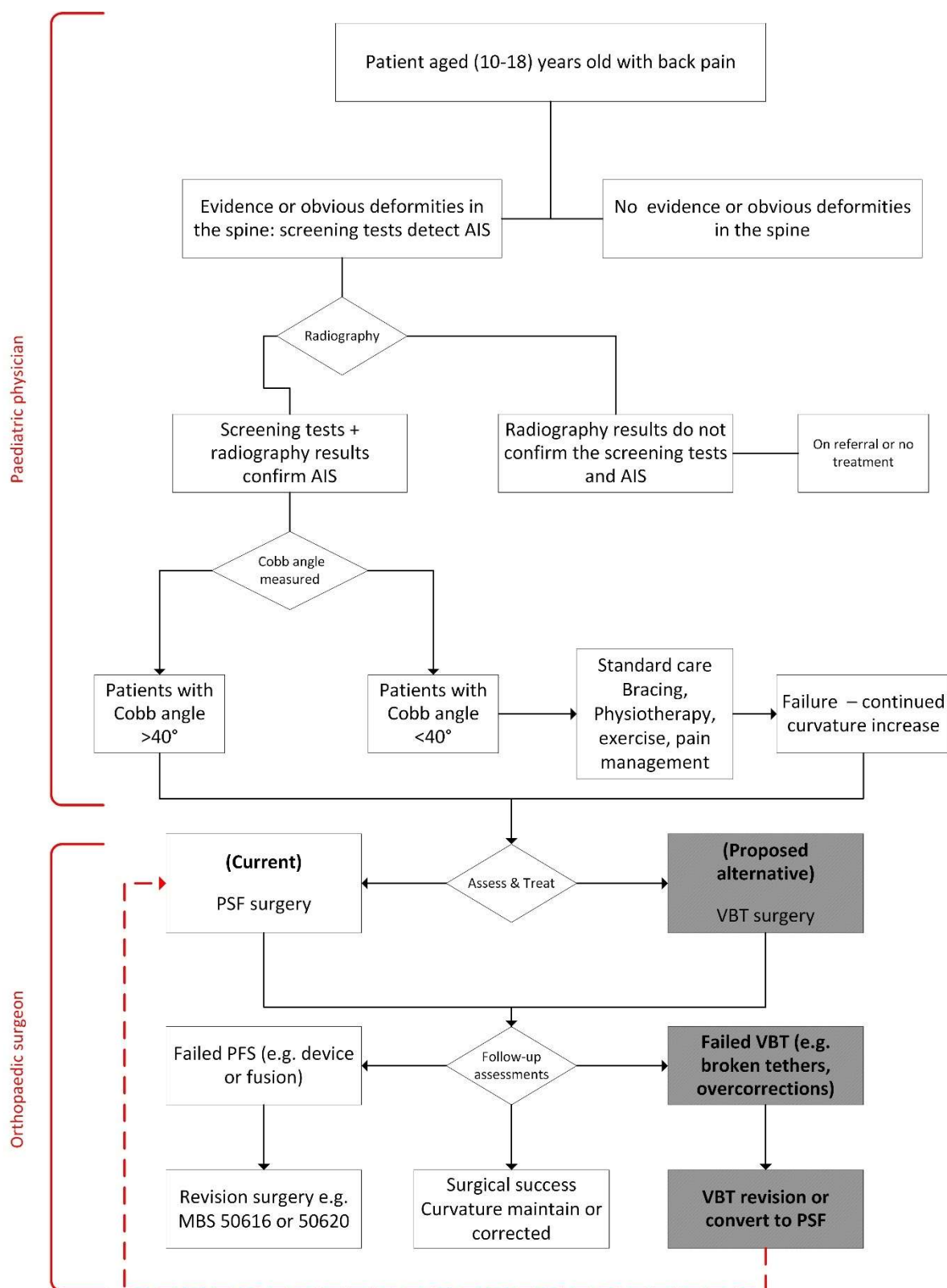


Figure 2: Current and proposed clinical management algorithm

PASC overall agreed with the current and future clinical management algorithms and suggested a minor amendment for clarity.

Proposed economic evaluation

Clinical Claim

The applicant's clinical claim is that VBT is superior to PSF for the management of AIS in terms of quality of life outcomes that may positively impact the psychological and emotional distress outcomes that resulted from spinal deformity, especially in adolescents aged 10 to 18 years old. In addition to a non-inferior curvature correction, VBT is also superior to PSF in term of functional benefits, including thoracic and lumbar angle of trunk rotations in patients with AIS, as PSF surgical outcome limits the spinal flexibility due to vertebral fusion.

- Compared to PSF, VBT has similar safety outcomes
- Compared to PSF, VBT is superior for quality of life
- Compared to PSF, VBT has similar clinical management pathway following the surgery
- Compared to PSF, recovery time after following VBT is expected to be quicker

PASC discussed if VBT would still be considered a minimally invasive procedure given that it may require a transthoracic or transabdominal approach. PASC noted the applicant's advice that it considered an anterior approach minimally invasive as although a different body cavity is accessed, recovery would be quick. However, PASC noted that such approaches raise specific safety issues, and that these need to be addressed at the assessment phase.

PASC agreed that high-quality evidence is needed to confirm VBT's clinical effectiveness and safety, including comparative studies of VBT versus PSF.

In a recent comparison study between VBT and PSF surgical procedures, some authors have outlined the preoperative and post-operative changes within both surgical procedure cohorts (Newton et al. 2020). Below is the summary of the preoperative and post-operative changes, which occurred in both groups (

Table 4).

Table 4: preoperative vs post-operative changes in both VBT and PSF surgical procedures.

VBT preoperative vs post-operative changes
There was a significant correction of the main thoracic curve obtained immediately postoperatively and was maintained at the final follow-up 2.3 years (range, 1.2 to 3.7 years). The lumbar curve was significantly smaller at the first postoperative visit and before any revision procedure. No significant preoperative to postoperative differences were observed in T2-T12 kyphosis or any clinical measures of deformity (Newton et al. 2020).
PSF preoperative vs post-operative changes
The main thoracic curve was significantly reduced immediately postoperatively, with a slight loss of correction at the time of the final follow-up 2.3 years (range, 1.2 to 3.7 years). All coronal curves were significantly corrected immediately postoperatively and remained significantly improved at the time of the final follow-up. T2-T12 kyphosis was significantly increased at the first postoperative visit but not at the time of final follow-up. Coronal imbalance showed significant improvement over the postoperative course, but finally with no differences from preoperatively (Newton et al. 2020).

Overall, it is claimed that VBT is superior in retaining spinal movement and reduction in hospital cost due to a reduced time to recovery and length of stay while achieving similar curve corrections to PSF for a similar safety profile. Thus, the most appropriate evaluation is a cost-effectiveness analysis (e.g. cost-utility analysis) to determine the procedure's cost relative to its effectiveness in achieving these outcomes.

PASC advised that the proposed economic analysis is a cost-effectiveness study or cost-utility analysis.

Proposed MBS item descriptor and MBS fee

The MBS item descriptors and associated fees proposed by the applicant are listed below:

Category 3 – Therapeutic Procedures – Surgical Operations
Proposed item descriptor: SCOLIOSIS, in a <i>skeletally mature</i> child or adolescent aged 10-18 years old with a Cobb angle of $\geq 40^\circ$, anterior correction of, with vertebral body tethering
<i>Note: Skeletal maturity is to be assessed using a validated bone age assessment tool</i>
Multiple Operation Rule (Anaes.) (Assist)
Proposed fee: \$3,534.05

Note: Highlighted text - suggested additions to the MBS descriptor to the target population of the PICO confirmation.

The associated fee is based on MBS item 50608. Whether the time and complexity of the VBT is equivalent to PSF needs to be determined. *PASC advised that time and complexity of VBT as compared with PSF needs to be confirmed at the assessment phase to justify the proposed MBS fees.*

Further, the item descriptor above is not limited to the proposed population requiring VBT procedure, especially in term of Cobb angle, age, and standard care failure in that population. This raises concerns of potential service leakage. Further, the applicant assumes the procedure's equivalency means VBT patients will be pulled from this cohort. However, the claim that VBT is a less invasive procedure may encourage more patients to undergo surgery, including electing surgery at an earlier stage.

PASC considered the applicant's proposed MBS item descriptor for VBT too broad and with a potential for service leakage outside the proposed population.

PASC advised that the MBS item descriptor should include a statement of skeletal maturity, Cobb angle and standard care failure. In addition, PASC advised that an explanatory note is required to define skeletal maturity is to be assessed using a validated method.

PASC agreed that the addition of idiopathic scoliosis to the MBS item descriptor (in the policy paper) may not be required.

PASC noted that VBT required co-administered services for anaesthesia and if required, for an assisting 'access surgeon' for anterior exposure of the spine. MBS Items 51160 and 51165 could be claimed by an assisting 'access surgeon' for the anterior exposure of the spine.

The applicant claims that revisions should be covered by an existing item (50616) if reworded as the following:

Category 3 – Therapeutic Procedures – Surgical Operations
Proposed item descriptor: SCOLIOSIS, in a child or adolescent re-exploration for adjustment or removal of segmental instrumentation vertebral body tethering instrumentation used for correction of spine deformity.
Proposed fee: \$3,534.05 \$638.70

Note: Highlighted text - applicant suggested rewording to the MBS descriptor to the target population of the PICO confirmation.

PASC should note that the proposed fee for revision is \$3,534.05 as compared with the current fee of \$638.70 for MBS 50616. However, MBS 50620 is also for revision of failed scoliosis surgery in child

or adolescent and attracts a fee of \$3,534.05. This may be the applicant's intended equivalent service for the revision of VBT.

The appropriate equivalent revision service and whether the time and complexity of revision for VBT is similar to PSF needs to be determined at the assessment phase.

PASC noted that the correct MBS fee for the proposed revision item was \$638.70 based on MBS item 50616, but that fee justification would be required at the assessment phase.

Consultation feedback

The department received targeted consultation responses from Scoliosis Australia and the Spine Society of Australia (SSA).

Scoliosis Australia supported the application and suggested that the MBS item descriptor should include a requirement to limit the intervention to a paediatric population under 16 years of age, in a growing spine.

The SSA generally supported the application with the following clarifications:

- SSA suggested a temporary MBS item number for use by clinicians with sufficient volume performance threshold in this field. Patient related outcomes could then be followed for 2-5 years until the patients are skeletally mature, with a review of the MBS items at 5 years
- SSA noted that VBT is technically demanding and specific training requirements and volume performance threshold should be considered
- SSA queried whether the current evidence would support the claim the VBT is superior to PSF, and higher quality evidence that but its exact role continues not to be defined and needs
- SSA queried the proposed fee, and referred to MBS items. In the paediatric spinal portion of the MBS schedule, the closest numbers are 50624 and 50628, but both of these procedures are not direct comparators. In the general spine portion of the MBS 51011-51171 there are appropriate direct comparator numbers: 51023 or 51024 for fixation of 3-6 motion segments; and 51165 for anterior approach to 2 or more motion segments which can be used by either the primary or approach surgeon.

PASC noted responses from targeted consultation from Scoliosis Australia and the Spine Society of Australia (SSA).

PASC noted that SSA considered a temporary MBS item number for use by clinicians with sufficient volume performance threshold in this field useful for follow up on patient related outcomes and review of the MBS item.

PASC noted that SSA queried the fee and referred to comparable MBS items on the paediatric and general spinal portion of the MBS. PASC discussed the comparators and confirmed that the current comparator item (50608) as listed in the PICO document is appropriate.

PASC also noted that SSA considered VBT a technically demanding intervention, and specific training and volume performance threshold should be considered.

PASC noted the feedback indicated a significant demand for VBT surgery, with families seeking the service overseas at a considerable personal expense. PASC noted that in Australia, surgeons were conservative in offering the service.

PASC advised that where possible, the assessment team should seek patient and stakeholder input.

Next steps

PASC advised that, upon ratification of the post-PASC PICO, the application can proceed to the Evaluation Sub-Committee (ESC) stage of the MSAC process.

PASC noted the applicant has elected to progress its application as an ADAR (applicant developed assessment report).

PASC advised the applicant to include evidence on patient outcomes from comparative studies of VBT versus PSF in their ADAR to MSAC, and noted recent publications by Newton et al, 2020 and Qiu et al 2021.

Applicant Comments on the PICO Confirmation

Nil.

Reference

Alanay, A, Yucekul, A, Abul, K, Ergene, G, Senay, S, Ay, B, Cebeci, BO, Dikmen, PY, Zulemyan, T & Yavuz, Y 2020, 'Thoracoscopic Vertebral Body Tethering for Adolescent Idiopathic Scoliosis: Follow-up Curve Behavior According to Sanders Skeletal Maturity Staging', *Spine*, vol. 45, no. 22, pp. E1483-E92.

Alharby, SW 2010, 'Anterior cruciate ligament injuries in growing skeleton', *International Journal of Health Sciences*, vol. 4, no. 1, pp. 71-9.

Asher, M 1980, 'A six-year report: spinal deformity screening in Kansas school children', *Journal of the Kansas Medical Society*, vol. 81, pp. 568-71.

Australian Institute of Health and Welfare 2021, *Procedures data cubes*, viewed 10/03 2021, <<https://www.aihw.gov.au/reports/hospitals/procedures-data-cubes/contents/data-cubes>>.

Baroncini, A, Trobisch, PD & Migliorini, F 2021, 'Learning curve for vertebral body tethering: analysis on 90 consecutive patients', *Spine Deformity*, vol. 9, no. 1, pp. 141-7.

Charles, YP, Daures, J-P, de Rosa, V & Diméglio, A 2006, 'Progression risk of idiopathic juvenile scoliosis during pubertal growth', *Spine*, vol. 31, no. 17, pp. 1933-42.

Cheung, JPY, Cheung, PWH, Yeng, WC & Chan, LCK 2020, 'Does Curve Regression Occur During Underarm Bracing in Patients with Adolescent Idiopathic Scoliosis?', *Clinical Orthopaedics and Related Research*, vol. 478, no. 2, pp. 334-45.

Cilli, K, Tezeren, G, Taş, T, Bulut, O, Oztürk, H, Oztemur, Z & Unsaldi, T 2009, 'School screening for scoliosis in Sivas, Turkey', *Acta Orthopaedica et Traumatologica Turcica*, vol. 43, no. 5, pp. 426-30.

Cobetto, N, Aubin, C-E & Parent, S 2018, 'Surgical Planning and Follow-up of Anterior Vertebral Body Growth Modulation in Pediatric Idiopathic Scoliosis Using a Patient-Specific Finite Element Model Integrating Growth Modulation', *Spine Deformity*, vol. 6, no. 4, pp. 344-50.

Courvoisier, A, Drevelle, X, Vialle, R, Dubousset, J & Skalli, W 2013, '3D analysis of brace treatment in idiopathic scoliosis', *European Spine Journal*, vol. 22, no. 11, pp. 2449-55.

Crawford, CHI & Lenke, LG 2010, 'Growth Modulation by Means of Anterior Tethering Resulting in Progressive Correction of Juvenile Idiopathic Scoliosis: A Case Report', *Journal of Bone and Joint Surgery*, vol. 92, no. 1, pp. 202-9.

D'Amato, CR, Griggs, S & McCoy, B 2001, 'Nighttime bracing with the Providence brace in adolescent girls with idiopathic scoliosis', *Spine (Phila Pa 1976)*, vol. 26, no. 18, pp. 2006-12.

Deyo, RA, Nachemson, A & Mirza, SK 2004, 'Spinal-fusion surgery—the case for restraint', *The Spine Journal*, vol. 4, no. 5, pp. S138-S42.

Dolan, LA & Weinstein, SL 2007, 'Surgical rates after observation and bracing for adolescent idiopathic scoliosis: an evidence-based review', *Spine*, vol. 32, no. 19, pp. S91-S100.

Ergene, G 2019, 'Early-term postoperative thoracic outcomes of videothoroscopic vertebral body tethering surgery', *Turkish Journal of Thoracic and Cardiovascular Surgery*, vol. 27, no. 4, p. 526.

Fadzan, M & Bettany-Saltikov, J 2017, 'Suppl-9, M3: Etiological Theories of Adolescent Idiopathic Scoliosis: Past and Present', *The Open Orthopaedics journal*, vol. 11, p. 1466.

Farady, JA 1983, 'Current principles in the nonoperative management of structural adolescent idiopathic scoliosis', *Physical Therapy*, vol. 63, no. 4, pp. 512-23.

Fayssoux, RS, Cho, RH & Herman, MJ 2010, 'A history of bracing for idiopathic scoliosis in North America', *Clinical Orthopaedics and Related Research*, vol. 468, no. 3, pp. 654-64.

FDA 2019, *The Tether™ - Vertebral Body Tethering System - H190005*, U.S Food & Drug Administration (FDA), viewed 03/03 2021, <<https://www.fda.gov/medical-devices/recently-approved-devices/tethertm-vertebral-body-tethering-system-h190005>>.

Guille, JT, D'Andrea, LP & Betz, RR 2007, 'Fusionless Treatment of Scoliosis', *Orthopedic Clinics of North America*, vol. 38, no. 4, pp. 541-5.

Hoernschemeyer, DG, Boeyer, ME, Robertson, ME, Loftis, CM, Worley, JR, Tweedy, NM, Gupta, SU, Duren, DL, Holzhauser, CM & Ramachandran, VM 2020, 'Anterior vertebral body tethering for adolescent scoliosis with growth remaining: a retrospective review of 2 to 5-year postoperative results', *Journal of Bone and Joint Surgery*, vol. 102, no. 13, pp. 1169-76.

Horne, JP, Flannery, R & Usman, S 2014, 'Adolescent idiopathic scoliosis: diagnosis and management', *American Family Physician*, vol. 89, no. 3, pp. 193-8.

Jobidon-Lavergne, H, Kadoury, S, Knez, D & Aubin, C-É 2019, 'Biomechanically driven intraoperative spine registration during navigated anterior vertebral body tethering', *Physics in Medicine & Biology*, vol. 64, no. 11, p. 115008.

JS, D, P, B, SO, C, U, R & HP, L 1985, 'Idiopathic scoliosis. Prevalence and ethnic distribution in Singapore schoolchildren', *Journal of Bone and Joint Surgery*, vol. 67-B, no. 2, pp. 182-4.

Kamtsiuris, P, Atzpodien, K, Ellert, U, Schlack, R & Schlaud, M 2007, 'Prevalence of somatic diseases in German children and adolescents. Results of the German Health Interview and Examination Survey for Children and Adolescents (KiGGS)', *Bundesgesundheitsblatt, Gesundheitsforschung, Gesundheitsschutz*, vol. 50, no. 5-6, pp. 686-700.

Karol, LA, Johnston 2nd, C, Browne, RH & Madison, M 1993, 'Progression of the curve in boys who have idiopathic scoliosis', *Journal of Bone and Joint Surgery*, vol. 75, no. 12, pp. 1804-10.

Konieczny, MR, Hüsseyin, S & Rüdiger, K 2013, 'Epidemiology of adolescent idiopathic scoliosis', *Journal of Children's Orthopaedics*, vol. 7, no. 1, pp. 3-9.

Lenke, LG, Bridwell, KH, Baldus, C, Blanke, K & Schoenecker, PL 1992, 'Cotrel-Dubousset instrumentation for adolescent idiopathic scoliosis', *Journal of Bone and Joint Surgery*, vol. 74, no. 7, pp. 1056-67.

Lonstein, JE, Bjorklund, S, Wanninger, MH & Nelson, RP 1982, 'Voluntary school screening for scoliosis in Minnesota', *Journal of Bone and Joint Surgery*, vol. 64, no. 4, pp. 481-8.

Mane, E, Veizaj, S & Mukaj, I 2018, 'Effects of physiotherapy on adolescent idiopathic scoliosis. A Systematic Review', *International Journal of Medicine & Healthcare*, vol. 3, no. 1, pp. 8-16.

Maruyama, T & Takeshita, K 2008, 'Surgical treatment of scoliosis: a review of techniques currently applied', *Scoliosis*, vol. 3, no. 1, pp. 1-6.

Merenda, L, Costello, K, Santangelo, AM & Mulcahey, MJ 2011, 'Perceptions of self-image and physical appearance: conversations with typically developing youth and youth with idiopathic scoliosis', *Orthopaedic Nursing*, vol. 30, no. 6, pp. 383-90.

Minkara, A, Bainton, N, Tanaka, M, Kung, J, DeAllie, C, Khaleel, A, Matsumoto, H, Vitale, M & Roye, B, 2020, 'High risk of mismatch between Sanders and Risser staging in adolescent idiopathic scoliosis: are we guiding treatment using the wrong classification?', *Journal of Pediatric Orthopaedics*, vol 40, no. 2, pp. 60-4.

Miyajima, F, Pawelek, J, Nasto, LA, Rushton, P, Simmonds, A & Parent, S 2020, 'Safety and efficacy of anterior vertebral body tethering in the treatment of idiopathic scoliosis: a multicentre review of 57 consecutive patients', *The Bone and Joint Journal*, vol. 102, no. 12, pp. 1703-8.

Nachemson, AL, Peterson, L-E, Bradford, D, Burwell, R, Duhaime, M, Edgar, M, Eppig, M, Gardner, A, Kehl, D & Lidstrom, J 1995, 'Effectiveness of treatment with a brace in girls who have adolescent idiopathic scoliosis. A prospective, controlled study based on data from the Brace Study of the Scoliosis Research Society', *Journal of Bone and Joint Surgery-Series A*, vol. 77, no. 6, pp. 815-22.

National Institute for Health and Care Excellence 2021, *Being monitored and out of remit procedures*, viewed 05/03 2021, <<https://www.nice.org.uk/about/what-we-do/our-programmes/nice-guidance/nice-interventional-procedures-guidance/ip-list>>.

Negrini, S, Negrini, A, Romano, M, Verzini, N, Negrini, A & Parzini, S 2006, 'A controlled prospective study on the efficacy of SEAS. 02 exercises in preventing progression and bracing in mild idiopathic scoliosis', *Studies in Health Technology and Informatics*, vol. 123, p. 523.

Nery, LS, Halpern, R, Nery, PC, Nehme, KP & Tetelbom Stein, A 2010, 'Prevalence of scoliosis among school students in a town in southern Brazil', *Sao Paulo Medical Journal*, vol. 128, pp. 69-73.

Newton, PO 2020, 'Spinal growth tethering: indications and limits', *Annals of Translational Medicine*, vol. 8, no. 2.

Newton, PO, Bartley, CE, Bastrom, TP, Kluck, DG, Saito, W & Yaszay, B 2020, 'Anterior Spinal Growth Modulation in Skeletally Immature Patients with Idiopathic Scoliosis: A Comparison with Posterior Spinal Fusion at 2 to 5 Years Postoperatively', *Journal of Bone and Joint Surgery*, vol. 102, no. 9, pp. 769-77.

Newton, PO, Kluck, DG, Saito, W, Yaszay, B, Bartley, CE & Bastrom, TP 2018, 'Anterior Spinal Growth Tethering for Skeletally Immature Patients with Scoliosis: A Retrospective Look Two to Four Years Postoperatively', *Journal of Bone and Joint Surgery*, vol. 100, no. 19, pp. 1691-7.

Newton, PO, Bartley, CE, Bastrom TP, Kluck, DG, Saito, W & Yaszay B 2020, 'Anterior Spinal Growth Modulation in Skeletally Immature Patients with Idiopathic Scoliosis: A Comparison with Posterior Spinal Fusion at 2 to 5 Years Postoperatively', *Journal of Bone and Joint Surgery*, vol 102, no. 9, pp.769-777.

NHS England 2018, Evidence review: Vertebral Body Tethering for Treatment of Idiopathic Scoliosis. Viewed 18/05/2021, <<https://www.england.nhs.uk/commissioning/wp-content/uploads/sites/12/2019/07/Vertebral-Body-Tethering-for-Scoliosis-Evidence-Review.pdf>>

Parr, A & Askin, G 2020, 'Paediatric scoliosis', *Australian Journal for General Practitioners*, vol. 49, pp. 832-7.

Pehlivanoglu, T, Oltulu, I, Oflluoglu, E, Sarioglu, E, Altun, G, Korkmaz, M, Yildirim, K & Aydogan, M 2020, 'Thoracoscopic Vertebral Body Tethering for Adolescent Idiopathic Scoliosis: A Minimum of 2 Years' Results of 21 Patients', *Journal of Pediatric Orthopaedics*, vol. 40, no. 10, pp. 575-80.

Qiu, C, Talwar, D, Gordon, J, Capraro, A, Lott, C & Cahil, PJ 2021, 'Patient-Reported Outcomes Are Equivalent in Patients Who Receive Vertebral Body Tethering Versus Posterior Spinal Fusion in Adolescent Idiopathic Scoliosis', *Orthopedics*, vol 44, no 1, pp. 24-8.

Rogala, EJ, Drummond, DS & Gurr, J 1978, 'Scoliosis: incidence and natural history. A prospective epidemiological study', *Journal of Bone and Joint Surgery*, vol. 60, no. 2, pp. 173-6.

Samdani, AF, Ames, RJ, Kimball, JS, Pahys, JM, Grewal, H, Pelletier, GJ & Betz, RR 2014, 'Anterior Vertebral Body Tethering for Idiopathic Scoliosis: Two-Year Results', *Spine*, vol. 39, no. 20, pp. 1688-93.

Samdani, AF, Ames, RJ, Kimball, JS, Pahys, JM, Grewal, H, Pelletier, GJ & Betz, RR 2015, 'Anterior vertebral body tethering for immature adolescent idiopathic scoliosis: one-year results on the first 32 patients', *European Spine Journal*, vol. 24, no. 7, pp. 1533-9.

Scoliosis Australia 2021, *Role Of The Family Doctor In The Management Of Scoliosis*, Scoliosis Australia, <<https://www.scoliosis-australia.org/policies-programs/role-of-the-family-doctor/>>.

Services Australia 2021, *Medicare Item Reports*, Services Australia, viewed 01/03 2021, <http://medicarestatistics.humanservices.gov.au/statistics/mbs_item.jsp>.

Soucacos, PN, Soucacos, PK, Zacharis, KC, Beres, AE & Xenakis, Ta 1997, 'School-Screening for Scoliosis. A Prospective Epidemiological Study in Northwestern and Central Greece', *Journal of Bone and Joint Surgery*, vol. 79, no. 10, pp. 1498-503.

Stokes, I 2002, 'Mechanical effects on skeletal growth', *Journal of Musculoskeletal and Neuronal Interactions*, vol. 2, no. 3, pp. 277-80.

Stokes, IAF, Aronsson, DD, Spence, H & Iatridis, JC 1998, 'Mechanical Modulation of Intervertebral Disc Thickness in Growing Rat Tails', *Clinical Spine Surgery*, vol. 11, no. 3, pp. 261-5.

Stokes, IAF, Spence, H, Aronsson, DD & Kilmer, N 1996, 'Mechanical Modulation of Vertebral Body Growth: Implications for Scoliosis Progression', *Spine*, vol. 21, no. 10, pp. 1162-7.

Sud, A & Tsirikos, AI 2013, 'Current concepts and controversies on adolescent idiopathic scoliosis: Part I', *Indian Journal of Orthopaedics*, vol. 47, no. 2, pp. 117-28.

Suh, S-W, Modi, HN, Yang, J-H & Hong, J-Y 2011, 'Idiopathic scoliosis in Korean schoolchildren: a prospective screening study of over 1 million children', *European Spine Journal*, vol. 20, no. 7, pp. 1087-94.

Tambe, A, Panikkar, S, Millner, P & Tsirikos, A 2018, 'Current concepts in the surgical management of adolescent idiopathic scoliosis', *Bone and Joint Journal*, vol. 100, no. 4, pp. 415-24.

Tarpada, SP, Morris, MT & Burton, DA 2017, 'Spinal fusion surgery: A historical perspective', *Journal of Orthopaedics*, vol. 14, no. 1, pp. 134-6.

Thirumala, P, Zhou, J, Natarajan, P, Balzer, J, Dixon, E, Okonkwo, D & Hamilton, D 2017, 'Perioperative neurologic complications during spinal fusion surgery: incidence and trends', *The Spine Journal*, vol. 17, no. 11, pp. 1611-24.

Villamor, GA, Andras, LM, Redding, G, Chan, P, Yang, J & Skaggs, DL 2019, 'A comparison of maximal voluntary ventilation and forced vital capacity in adolescent idiopathic scoliosis patients', *Spine Deformity*, vol. 7, no. 5, pp. 729-33.

Wan, L, Wang, GX & Rong, B 2005, 'Results of exercise therapy in treatment of essentially S-shaped scoliosis patients: evaluations of Cobbs angle in the breast and lumbar segment', *Chinese Journal of Clinical Rehabilitation*, vol. 9, pp. 82-4.

Weinstein, SL, Dolan, LA, Cheng, JCY, Danielsson, A & Morcuende, JA 2008, 'Adolescent idiopathic scoliosis', *The Lancet*, vol. 371, no. 9623, pp. 1527-37.

Weinstein, SL, Dolan, LA, Wright, JG & Dobbs, MB 2013, 'Effects of bracing in adolescents with idiopathic scoliosis', *New England Journal of Medicine*, vol. 369, no. 16, pp. 1512-21.

Weiss, H-R, Turnbull, D, Seibel, S & Kleban, A 2019, 'First end-result of a prospective cohort with AIS treated with a CAD Chêneau style brace', *Journal of Physical Therapy Science*, vol. 31, no. 12, pp. 983-91.

Wong, H-K, Ruiz, JNM, Newton, PO & Liu, K-PG 2019, 'Non-fusion surgical correction of thoracic idiopathic scoliosis using a novel, braided vertebral body tethering device: minimum follow-up of 4 years', *Journal of Bone and Joint Surgery Open Access*, vol. 4, no. 4.

Yin, S, Tao, H, Du, H, Feng, C, Yang, Y, Yang, W & Duan, C 2018, 'Postoperative pulmonary complications following posterior spinal instrumentation and fusion for congenital scoliosis', *PloS one*, vol. 13, no. 11, p. e0207657.

Zhu, Z, Xu, L, Jiang, L, Sun, X, Qiao, J, Qian, B-P, Mao, S & Qiu, Y 2017, 'Is brace treatment appropriate for adolescent idiopathic scoliosis patients refusing surgery with Cobb angle between 40 and 50 degrees', *Clinical Spine Surgery*, vol. 30, no. 2, pp. 85-9.

Appendix

Table 5 Aggregate counts of posterior spinal fusion procedures in Australia (2018 - 2019) (Australian Institute of Health and Welfare 2021)

Procedure chapter	Procedure sub-chapter	Procedure block	Procedure code	Age Group	Sex	Same-day Flag	Procedures
15 Procedures on musculoskeletal system	1381-1393 Spine (Vertebral Column)	1389 Spinal fusion	48642-00 Posterior spinal fusion, 1 or 2 levels	04- Age 10-14 yrs	1- Male	2- Overnight	8
15 Procedures on musculoskeletal system	1381-1393 Spine (Vertebral Column)	1389 Spinal fusion	48642-00 Posterior spinal fusion, 1 or 2 levels	04- Age 10-14 yrs	2- Female	1- Same day	1
15 Procedures on musculoskeletal system	1381-1393 Spine (Vertebral Column)	1389 Spinal fusion	48642-00 Posterior spinal fusion, 1 or 2 levels	04- Age 10-14 yrs	2- Female	2- Overnight	23
15 Procedures on musculoskeletal system	1381-1393 Spine (Vertebral Column)	1389 Spinal fusion	48642-00 Posterior spinal fusion, 1 or 2 levels	05- Age 15-19 yrs	1- Male	2- Overnight	20
15 Procedures on musculoskeletal system	1381-1393 Spine (Vertebral Column)	1389 Spinal fusion	48642-00 Posterior spinal fusion, 1 or 2 levels	05- Age 15-19 yrs	2- Female	2- Overnight	23
15 Procedures on musculoskeletal system	1381-1393 Spine (Vertebral Column)	1389 Spinal fusion	48645-00 Posterior spinal fusion, 3 or more levels	04- Age 10-14 yrs	1- Male	1- Same day	3
15 Procedures on musculoskeletal system	1381-1393 Spine (Vertebral Column)	1389 Spinal fusion	48645-00 Posterior spinal fusion, 3 or more levels	04- Age 10-14 yrs	1- Male	2- Overnight	48
15 Procedures on musculoskeletal system	1381-1393 Spine (Vertebral Column)	1389 Spinal fusion	48645-00 Posterior spinal fusion, 3 or more levels	04- Age 10-14 yrs	2- Female	1- Same day	2
15 Procedures on musculoskeletal system	1381-1393 Spine (Vertebral Column)	1389 Spinal fusion	48645-00 Posterior spinal fusion, 3 or more levels	04- Age 10-14 yrs	2- Female	2- Overnight	182
15 Procedures on musculoskeletal system	1381-1393 Spine (Vertebral Column)	1389 Spinal fusion	48645-00 Posterior spinal fusion, 3 or more levels	05- Age 15-19 yrs	1- Male	1- Same day	2
15 Procedures on musculoskeletal system	1381-1393 Spine (Vertebral Column)	1389 Spinal fusion	48645-00 Posterior spinal fusion, 3 or more levels	05- Age 15-19 yrs	1- Male	2- Overnight	126
Procedure chapter	Procedure sub-chapter	Procedure block	Procedure code	Age Group	Sex	Same-day Flag	Procedures
15 Procedures on musculoskeletal system	1381-1393 Spine (Vertebral Column)	1389 Spinal fusion	48645-00 Posterior spinal fusion,	05- Age 15-19 yrs	2- Female	2- Overnight	171

Procedure chapter	Procedure sub-chapter	Procedure block	Procedure code	Age Group	Sex	Same-day Flag	Procedures
			3 or more levels				
15 Procedures on musculoskeletal system	1381-1393 Spine (Vertebral Column)	1389 Spinal fusion	48648-00 Posterolateral spinal fusion, 1 or 2 levels	04- Age 10-14 yrs	1- Male	2- Overnight	1
15 Procedures on musculoskeletal system	1381-1393 Spine (Vertebral Column)	1389 Spinal fusion	48648-00 Posterolateral spinal fusion, 1 or 2 levels	04- Age 10-14 yrs	2- Female	2- Overnight	3
15 Procedures on musculoskeletal system	1381-1393 Spine (Vertebral Column)	1389 Spinal fusion	48648-00 Posterolateral spinal fusion, 1 or 2 levels	05- Age 15-19 yrs	1- Male	2- Overnight	4
15 Procedures on musculoskeletal system	1381-1393 Spine (Vertebral Column)	1389 Spinal fusion	48648-00 Posterolateral spinal fusion, 1 or 2 levels	05- Age 15-19 yrs	2- Female	2- Overnight	1
15 Procedures on musculoskeletal system	1381-1393 Spine (Vertebral Column)	1389 Spinal fusion	48651-00 Posterolateral spinal fusion, 3 or more levels	04- Age 10-14 yrs	1- Male	2- Overnight	3
15 Procedures on musculoskeletal system	1381-1393 Spine (Vertebral Column)	1389 Spinal fusion	48651-00 Posterolateral spinal fusion, 3 or more levels	04- Age 10-14 yrs	2- Female	2- Overnight	5
15 Procedures on musculoskeletal system	1381-1393 Spine (Vertebral Column)	1389 Spinal fusion	48651-00 Posterolateral spinal fusion, 3 or more levels	05- Age 15-19 yrs	1- Male	2- Overnight	3
15 Procedures on musculoskeletal system	1381-1393 Spine (Vertebral Column)	1389 Spinal fusion	48651-00 Posterolateral spinal fusion, 3 or more levels	05- Age 15-19 yrs	2- Female	2- Overnight	7
15 Procedures on musculoskeletal system	1381-1393 Spine (Vertebral Column)	1389 Spinal fusion	48654-00 Posterior spinal fusion with laminectomy, 1 level	05- Age 15-19 yrs	1- Male	2- Overnight	2
Procedure chapter	Procedure sub-chapter	Procedure block	Procedure code	Age Group	Sex	Same-day Flag	Procedures
15 Procedures on musculoskeletal system	1381-1393 Spine (Vertebral Column)	1389 Spinal fusion	48654-00 Posterior spinal fusion with laminectomy, 1 level	05- Age 15-19 yrs	2- Female	2- Overnight	4
15 Procedures on musculoskeletal system	1381-1393 Spine (Vertebral Column)	1389 Spinal fusion	48654-01 Posterolateral spinal fusion with laminectomy, 1 level	04- Age 10-14 yrs	2- Female	2- Overnight	5

Procedure chapter	Procedure sub-chapter	Procedure block	Procedure code	Age Group	Sex	Same-day Flag	Procedures
15 Procedures on musculoskeletal system	1381-1393 Spine (Vertebral Column)	1389 Spinal fusion	48654-01 Posterolateral spinal fusion with laminectomy, 1 level	05- Age 15-19 yrs	1- Male	2- Overnight	2
15 Procedures on musculoskeletal system	1381-1393 Spine (Vertebral Column)	1389 Spinal fusion	48654-01 Posterolateral spinal fusion with laminectomy, 1 level	05- Age 15-19 yrs	2- Female	2- Overnight	1
15 Procedures on musculoskeletal system	1381-1393 Spine (Vertebral Column)	1389 Spinal fusion	48657-00 Posterior spinal fusion with laminectomy, 2 or more levels	04- Age 10-14 yrs	1- Male	2- Overnight	3
15 Procedures on musculoskeletal system	1381-1393 Spine (Vertebral Column)	1389 Spinal fusion	48657-00 Posterior spinal fusion with laminectomy, 2 or more levels	04- Age 10-14 yrs	2- Female	2- Overnight	13
15 Procedures on musculoskeletal system	1381-1393 Spine (Vertebral Column)	1389 Spinal fusion	48657-00 Posterior spinal fusion with laminectomy, 2 or more levels	05- Age 15-19 yrs	1- Male	2- Overnight	7
15 Procedures on musculoskeletal system	1381-1393 Spine (Vertebral Column)	1389 Spinal fusion	48657-00 Posterior spinal fusion with laminectomy, 2 or more levels	05- Age 15-19 yrs	2- Female	2- Overnight	6
Procedure chapter	Procedure sub-chapter	Procedure block	Procedure code	Age Group	Sex	Same-day Flag	Procedures
15 Procedures on musculoskeletal system	1381-1393 Spine (Vertebral Column)	1389 Spinal fusion	48657-01 Posterolateral spinal fusion with laminectomy, 2 or more levels	04- Age 10-14 yrs	1- Male	1- Same day	1
15 Procedures on musculoskeletal system	1381-1393 Spine (Vertebral Column)	1389 Spinal fusion	48657-01 Posterolateral spinal fusion with laminectomy, 2 or more levels	05- Age 15-19 yrs	1- Male	2- Overnight	1

Procedure chapter	Procedure sub-chapter	Procedure block	Procedure code	Age Group	Sex	Same-day Flag	Procedures
15 Procedures on musculoskeletal system	1381-1393 Spine (Vertebral Column)	1389 Spinal fusion	48657-01 Posterolateral spinal fusion with laminectomy, 2 or more levels	05- Age 15-19 yrs	2- Female	2- Overnight	1
Total							682