



Australian Government

Department of Health

Ratified

PICO Confirmation

Application 1661

**Implantation of minimally invasive
interspinous decompression spacers
for moderate degenerative lumbar
spinal stenosis**

Summary of PICO/PPICO criteria to define the question(s) to be addressed in an Assessment Report to the Medical Services Advisory Committee (MSAC)

Component	Description
Patients	<p>Skeletally mature patients with all of the following:</p> <ul style="list-style-type: none"> • neurogenic intermittent claudication secondary to a diagnosis of moderate degenerative lumbar spinal stenosis*, with or without grade 1 spondylolisthesis (on a scale of 1 to 4), confirmed by X-ray, magnetic resonance imaging (MRI) and/or computed tomography (CT) evidence of thickened ligamentum flavum, narrowed lateral recess and/or central canal or foraminal narrowing • impaired physical function and symptoms of leg/buttock/groin pain that are relieved in flexion, with or without back pain, who have undergone at least 6 months of non-operative treatment • an indication for treatment at no more than two levels, from L1 to L5 <p>*Defined as a 25-50% reduction in the central canal and/or nerve root canal (subarticular, neuroforaminal) compared with the adjacent levels on radiographic studies, with radiographic confirmation of any one of the following:</p> <ul style="list-style-type: none"> • evidence of thecal sac and/or cauda equina compression • evidence of nerve root displacement or compression by either osseous or non-osseous elements • evidence of hypertrophic facets with canal encroachment <p>AND the following clinical signs:</p> <ul style="list-style-type: none"> • moderately impaired physical function (≥ 2 of the Zurich Claudication Questionnaire) • ability to sit for 50 minutes without pain and to walk ≥ 50 feet
Intervention	Minimally invasive interspinous decompression spacers (Superion™ Indirect Decompression System)
Comparator	<ul style="list-style-type: none"> • A weighted comparator of laminectomy with or without spinal fusion
Outcomes	<p>Primary effectiveness outcomes:</p> <ul style="list-style-type: none"> • Disability and functional status • Pain intensity • New or persistent worsened neurological deficit at the index level(s) • Objective measure of walking capacity <p>Secondary effectiveness outcomes:</p> <ul style="list-style-type: none"> • Time to return to daily activities • Patient satisfaction • Health-related quality of life <p>Safety outcomes:</p> <ul style="list-style-type: none"> • Device- and procedure-related complications • Number of reoperations, removals or revisions • Need for subsequent intervention

Component	Description
	Healthcare system outcomes: <ul style="list-style-type: none"> • Number of patients eligible for the implant • Device and procedure costs • Cost of complications related to the procedure • Cost of additional interventions related to device failure • Follow-up utilisation of healthcare resources after successful device implantation

PICO or PPICO rationale for therapeutic and investigative medical services only

Population

The proposed Superior™ Indirect Decompression System (Boston Scientific Corporation, USA) is for patients with moderate degenerative lumbar spinal stenosis (LSS), with or without mild degenerative spondylolisthesis, whose symptoms have not improved after six months of conservative management.

LSS refers to narrowing of the central spinal canal, lateral recesses or intervertebral foramen in the low back region as a result of congenital or acquired conditions (Raja et al. 2021). Acquired LSS (>90% of cases) can arise from trauma, degenerative changes, iatrogenic causes and systemic processes, such as neoplasms or skeletal diseases. The leading cause of acquired LSS is degenerative changes resulting from osteoarthritis, disc protrusion or bulging, facet joint arthropathy, osteophyte formation, ligament thickening or other age-related structural alterations (Chen et al. 2019; Kalichman et al. 2009; Poetscher et al. 2018). Degenerative LSS occurs most frequently at the L4 to L5 level in the spine, followed by L5 through S1 and L3 to L4. Degenerative lumbar spondylolisthesis, where one lumbar vertebra slips out of place onto the bone below it, may also be present, potentially causing spinal instability and exacerbating spinal canal narrowing (Ahmed et al. 2018; Munakomi, Foris & Varacallo 2021).

The mechanical compression of surrounding neurovascular structures by LSS produces various symptoms depending on which nerves are affected (Munakomi, Foris & Varacallo 2021). The hall mark symptom of spinal stenosis is pain, numbness, weakness or tingling in the thigh, buttocks or legs, with or without back pain, that is exacerbated by walking (neurogenic claudication) or prolonged standing and is alleviated with forward flexion or sitting. When spinal stenosis predominantly affects the intervertebral foramen or lateral recess, patients usually experience radicular pain (Cairns et al. 2019; Poetscher et al. 2018). Symptoms of more pronounced LSS include muscle weakness, balance problems, loss of sexual ability and, in severe cases, cauda equina syndrome (Andreisek, Hodler & Steurer 2011; Chen et al. 2019; Kreiner et al. 2011; Munakomi, Foris & Varacallo 2021).

Prognosis

There is no clear-cut association between abnormalities observed on spinal imaging studies and clinical symptoms in patients with degenerative LSS. Clinical symptoms may remain static despite progression of narrowing, may progress in the absence of a change in anatomic structures or may be

vastly different between two patients with identical degrees of anatomical stenosis (Andreisek, Hodler & Steurer 2011; Kuitinen et al. 2014; Lohman et al. 2006). Consequently, while most individuals older than 60 years have some degree of spinal stenosis, few are symptomatic (Andreisek, Hodler & Steurer 2011; Deer et al. 2019; Munakomi, Foris & Varacallo 2021). A cross-sectional study of 938 individuals found that only 18% of those with radiographically severe central stenosis had clinical symptoms (Ishimoto et al. 2013). Nonetheless, degenerative LSS is a progressive condition. Once clinical symptoms appear, they generally progress over time, resulting in significant reductions in mobility, function, activities of daily living and health-related quality of life (Deer et al. 2019; Munakomi, Foris & Varacallo 2021; Otani et al. 2013; Overvest et al. 2015).

Prevalence

Epidemiological study of degenerative LSS is challenging due to the absence of universally accepted radiologic criteria for quantifying spinal stenosis, the lack of correlation between anatomic changes and clinical symptoms and the fact that population estimates do not always distinguish between congenital and acquired LSS (Lohman et al. 2006; Yabuki et al. 2013). (Otani et al. 2013; Wu & Cruz 2021). Consequently, the exact prevalence of degenerative LSS in Australia is unknown. However, a recent meta-analysis reported a mean prevalence of degenerative LSS in the general population of 11% based on clinical diagnosis and 38% based on radiological diagnosis—the prevalence in an asymptomatic population was 11% (Jensen et al. 2020). The incidence of degenerative LSS increases with age, as evidenced by a Japanese population-based study reporting an incidence of 2% among people aged 40 to 49 years and 11% among those aged 70 to 79 years (Yabuki et al. 2013). Similarly, an ancillary Framingham Study reported that acquired LSS increased from 4% among people younger than 40 years to 14% in those aged 60 years or older (Kalichman et al. 2009).

Declining birth rates and increased life expectancy have resulted in a significant increase in the number and proportion of older people in Australia. In 2017, 3.8 million or 15% of the total population (one in seven) were aged 65 years or older (Australian Institute of Health and Welfare 2018); by 2030 this number is projected to increase to 5.7 million people or one in five (Australian Government Department of Health and Ageing 2008).

The prevalence of LSS in Australia is unknown.

Rationale

The effectiveness of treatments for degenerative LSS depends on the accuracy of the diagnosis, which can be challenging since no universal gold standard for LSS diagnosis has been established. Since clinical symptoms do not necessarily correlate with the degree of spinal canal narrowing visible in imaging studies, the diagnosis of degenerative LSS is typically based on the combination of symptoms, clinical examination results and radiologic findings (Deer et al. 2019; Kreiner et al. 2011; Wu & Cruz 2021). The North American Spine Society (NASS) guidelines recommend that patients with history and physical examination findings consistent with degenerative LSS undergo MRI of the lumbosacral spine to confirm the presence of anatomic narrowing of the spinal canal or nerve root impingement. CT or CT myelography is an option when MRI is inconclusive or unfeasible (Kreiner et al. 2011; Zileli et al. 2020). The criteria most frequently used to quantify anatomic central and lateral narrowing on imaging studies is based on the compression ratio relative to normal size as follows:

mild <1/3 compression; moderate 1/3 to 2/3; and severe >2/3 (Andreisek et al. 2013; Deer et al. 2019).

PASC noted the difficulty of defining what constitutes moderate LSS in terms of radiologic and clinical criteria given the current lack of universally agreed diagnostic criteria and the lack of correlation between radiologic and clinical symptoms and signs of LSS in many patients. This is further complicated in cases with co-existing low-grade lumbar spondylolisthesis.

There is no standardised treatment approach for patients with degenerative LSS, so treatment plans vary and are often guided by clinical judgement (Kreiner et al. 2011; Parker et al. 2015). Guideline recommended first-line treatment for mild to moderate degenerative LSS (with or without degenerative lumbar spondylolisthesis) involves various conservative interventions, depending on the location of the stenosis and the severity of symptoms. These include medication (e.g., anti-inflammatory drugs and analgesics), physiotherapy, spinal manipulation, electrical stimulation, acupuncture, steroid injections, cognitive behavioural therapy, lumbosacral braces and multidisciplinary patient education (Ahmed et al. 2018; Andreisek, Hodler & Steurer 2011; Fornari et al. 2020; Kreiner et al. 2011).

Rapid or catastrophic neurologic decline is rare in patients with clinically mild to moderate symptomatic degenerative LSS, and approximately 30% of patients improve with conservative measures over a period of two to 10 years. Conversely, 20-40% will experience worsening of symptoms and will ultimately require surgery (Kreiner et al. 2011; Wu & Cruz 2021; Zileli et al. 2020). Surgery for moderate LSS is generally considered elective as its purpose is to alleviate symptoms and improve function rather than to prevent neurologic impairment (Deer et al. 2019). Consequently, spinal surgery is a last resort for treating degenerative LSS and is reserved for patients with severe symptoms or patients whose symptoms have not improved after at least six months of conservative therapy (Australian Commission on Safety and Quality in Health Care 2017; Kreiner et al. 2011).

The proposed indications for the Superior device are in line with guideline-recommended indications and the randomised controlled trial conducted to support an Investigational Device Exemption and Premarket Approval application to the United States Food and Drug Administration (US FDA) (Table 1) (Costa et al. 2020; Deer et al. 2019; Kreiner et al. 2011; Patel, Whang, et al. 2015; US FDA 2015). Only patients aged 45 years or older were eligible to participate in the pivotal trial.

Table 1: Indications and contraindications for the Superion Indirect Decompression System (US FDA 2015; VertiFlex® 2015)

Indications	Contraindications
<p>Skeletally mature patients with the following:</p> <ul style="list-style-type: none"> • neurogenic intermittent claudication secondary to a diagnosis of moderate degenerative lumbar spinal stenosis*, with or without grade 1 spondylolisthesis (on a scale of 1 to 4)^a, confirmed by X-ray, MRI and/or CT evidence of thickened ligamentum flavum, narrowed lateral recess, and/or central canal or foraminal narrowing • impaired physical function and symptoms of leg/buttock/groin pain that are relieved in flexion, with or without back pain, who have undergone at least 6 months of non-operative treatment • an indication for treatment at no more than two levels, from L1 to L5 	<p>Patients with any of the following:</p> <ul style="list-style-type: none"> • an allergy to titanium/titanium alloy • spinal anatomy or disease that would prevent device implantation or cause the device to be unstable in situ (e.g., isthmic spondylolisthesis or degenerative spondylolisthesis >grade 1 [on a scale of 1 to 4]); an ankylosed segment at the affected level(s); fracture of the spinous process, pars interarticularis or laminae (unilateral or bilateral); or scoliosis (Cobb angle >10°) • cauda equina syndrome • severe osteoporosis, defined as bone mineral density in the spine or hip >2.5 standard deviations below the mean of adult normals • active systemic infection or infection localised to the site of implantation • prior fusion or decompression procedure at the index level • morbid obesity (body mass index >40 kg/m²) <p>There is an increased risk of spinous process fractures in patients with either of the following:</p> <ul style="list-style-type: none"> • thin or “gracile” spinous processes • spinous processes that are in very close approximation or in contact (“kissing”)
<p>*Defined as a 25-50% reduction in the central canal and/or nerve root canal (subarticular, neuroforaminal) compared with the adjacent levels on radiographic studies, with radiographic confirmation of any one of the following:</p> <ul style="list-style-type: none"> • evidence of thecal sac and/or cauda equina compression • evidence of nerve root displacement or compression by either osseous or non-osseous elements • evidence of hypertrophic facets with canal encroachment <p>AND the following clinical signs:</p> <ul style="list-style-type: none"> • moderately impaired physical function (≥2 of the Zurich Claudication Questionnaire) • ability to sit for 50 minutes without pain and to walk ≥50 feet 	

CT: computed tomography; MRI: magnetic resonance imaging

^aClassification of spondylolisthesis is based on the degree of shifting of one vertebral body anteriorly or posteriorly relative to an adjacent vertebral body in the spine as follows: grade 1 is shifting of <25%; grade 2 is 25–50%; grade 3 is 50–75%; grade 4 is 75–100% (grade 5, spondyloptosis, is >100%) (Deer et al. 2019)

Based on the exclusion criteria used in the US FDA pivotal trial, the presence of any of the conditions listed in Box 1 is a contraindication for implanting the Superior device.

Box 1: Additional clinical exclusion criteria for the Superior Indirect Decompression System pivotal trial (US FDA 2015)

1. Axial back pain only
2. Fixed motor deficit
3. Lumbar spinal stenosis requiring a surgical intervention in addition to the device implantation procedure
4. Unremitting pain in any spinal position
5. Significant peripheral neuropathy or acute denervation secondary to radiculopathy
6. Significant instability of the lumbar spine defined as ≥ 3 mm translation or $\geq 5^\circ$ angulation
7. Sustained pathologic fractures of the vertebrae or multiple fractures of the vertebrae and/or hips
8. Spondylolysis (pars fracture)
9. Insulin-dependent diabetes mellitus or angina
10. Significant peripheral vascular disease (diminished dorsalis pedis or tibial pulses)
11. Infection in the disc or spine, past or present
12. Active systemic disease such as AIDS, HIV, hepatitis, etc.
13. Paget's disease at the involved segment or metastasis to the vertebra; osteomalacia or other metabolic bone disease
14. Currently undergoing immunosuppressive therapy or long-term steroid use
15. Tumour in the spine or a malignant tumour, except for basal cell carcinoma
16. Life expectancy of less than two years
17. Active rheumatoid arthritis or any other systemic disease
18. Pregnant or lactating

PASC noted that in the United States Food and Drug Administration (US FDA) pivotal trial only skeletally mature patients aged 45 years or older were eligible to participate, which is not reflected in the application or item descriptor.

PASC noted the difficulty of having very specific selection criteria for a condition that may have a wide variety of presentations in order to define those who would benefit the most from a particular procedure.

PASC confirmed that, notwithstanding concerns raised regarding the patient selection criteria, the appropriate patient group is that defined in the US FDA pivotal trial (Table 1 and Box 1).

Previous MSAC Applications

The applicant noted that there have been two previous applications to the MSAC for interspinous decompression spacers. In 2007, a contracted assessment (MSAC Application 1099) compared the safety, effectiveness and cost-effectiveness of a pedicle screw device (Dynesys®) and interspinous decompression spacers (the Coflex® Interlaminar Stabilization® Device, X-STOP® Interspinous Process Decompression System, Wallis System and Device for Intervertebral Assisted Motion) with laminectomy, with or without conventional spinal fusion. In 2017, an applicant developed report (MSAC Application 1422) examined the safety, effectiveness and cost-effectiveness of the Coflex device plus decompression surgery, compared with decompression surgery plus instrumented fusion (which was considered inappropriate by the MSAC). Both applications were rejected by the MSAC due to insufficient evidence for effectiveness. Among these proposed devices, only the X-STOP was, like Superior, a minimally invasive stand-alone implant that does not require open surgery; the

other devices are designed to be used in conjunction with surgical decompression. The population nominated in the current submission is similar to that for the X STOP device (US FDA 2005).

Intervention

The Superior Indirect Decompression System is a titanium device that is placed between the spinous processes of the lumbar spine. It is inserted percutaneously via a tube through a small incision (<2.5 cm) in the lower back under fluoroscopic guidance. The procedure is performed under local anaesthesia with conscious sedation on an outpatient basis and takes between 45-60 minutes. Once in place, the two “wings” of the device are deployed to brace against the lateral aspects of the superior and inferior spinous processes, creating a space between them. The procedure causes no tissue or bone damage and results in minimal blood loss. The Superior device is designed to be implanted at no more than two adjacent lumbar levels, from L1 to L5, and is available in five different sizes, depending on the degree of interspinous decompression or spacing required (US FDA 2015; VertiFlex® 2015).

The Superior Indirect Decompression System comprises a single-use titanium lumbar interspinous decompression spacer and a proprietary instrument kit, both of which were listed on the Australian Register of Therapeutic Goods (ARTG) in April 2020 (Table 2). The device is not currently funded in Australia, but an application will be made to list the Superior device on the Prostheses List.

The applicant indicated that patients eligible to receive the device would be referred by a consultant pain specialist, neurosurgeon or orthopaedic surgeon after an unsuccessful six-month trial of conservative management. The minimally invasive implantation procedure can be performed by an interventional pain specialist in a day surgery setting. An anaesthetist may be required to administer and monitor patient sedation. The training required to implant the Superior device is similar to that for other implantable devices, such as spinal cord stimulators, so no additional training is required. While neurosurgeons and spine and orthopaedic surgeons can also perform this procedure, the applicant advised that this is likely to occur in less than 15% of cases. In the event of treatment failure, the applicant advised that the device can be removed in the same manner and setting as it was implanted.

PASC noted that the interventional pain specialists who would most likely do the bulk of the Superior procedures would require additional training in the technical skills required for implanting the device as well as in the extensive clinical and anatomical criteria required to select the appropriate patient group.

It is expected that patients will require one medical service per lifetime. However, additional services for revision or removal of the device may be required if complications arise postoperatively. Based on current utilisation of one and two-level laminectomies (Medicare Benefits Schedule (MBS) items 51011 and 51012), the applicant expects that approximately 31% of patients eligible for the proposed device will be implanted at two levels.

Table 2: Listing on the Australian Register of Therapeutic Goods

ARTG ID/Product	Intended Purpose
334411 Medical Device Class IIb Lumbar interspinous decompression spacer, sterile	To provide posterior stabilisation of the lumbar spine, levels L1 to L5, via a percutaneous/minimally invasive procedure
333162 Medical Device Class IIa Superion Indirect Decompression Instrument Kit - Lumbar interspinous decompression instrument set, single-use	The single-use manual instruments are employed to access the interspinous process space and to position the Superion implant

Utilisation data for MBS items 51011 and 51012 indicate that 14,406 and 6,470 decompression procedures were performed, respectively, in 2020. The applicant used data from MSAC Application 1099, which included the X-STOP device, to estimate the proportion of patients undergoing single-level (10-20%) or multiple level (10-30%) laminectomies that would be eligible to receive an interspinous decompression device. Applying the upper limit of these ranges to the number of patients receiving one and two-level laminectomies in 2020 gives a conservative estimate of 1,941-2,881 candidates per year. The applicant expects an uptake of 5% in the first year of listing, which gives an estimated utilisation of 97-144 patients annually, and annual growth rates of 7% and 3% for MBS items 51011 and 51012 based on utilisation from 2010 to 2017. While it is reasonable to base utilisation estimates on MBS claims for comparator procedures, these estimates do not take into account the following factors: the listed services are provided to other patient groups who are not indicated for the proposed intervention; multiple items may have been claimed for a single procedure; and the number of additional patients currently ineligible for surgery who would potentially be candidates for the proposed intervention. Thus, the exact size of the population that would be eligible for the Superion procedure is unknown.

It was noted that 10-15% of patients with moderate LSS would be eligible for the Superion device.

PASC noted that the Spine Society of Australia advised that the Superion device is not generally used by spinal surgeons in Australia. However, PASC noted the applicant anticipated it would be used predominantly by pain specialists (rather than spinal surgeons).

The applicant expects the uptake of the Superion procedure to rise to 15% once neurosurgeons become familiar with the procedure. However, it is unlikely that the service will be used in populations other than that nominated in the proposed listing, as there is no clinical need or evidence of effectiveness in other groups.

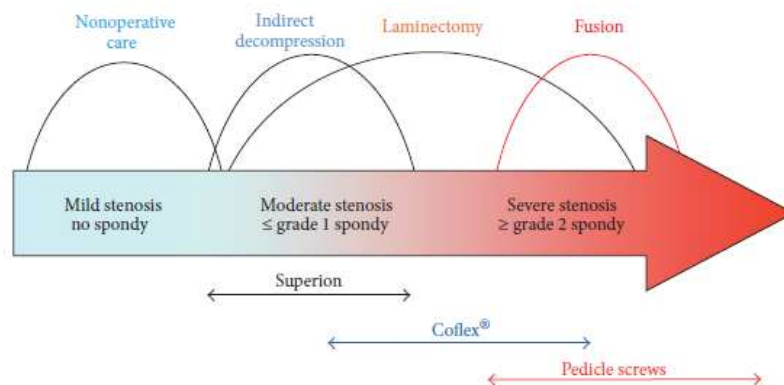
Rationale

Degenerative LSS is predominantly a disease of the elderly, many of whom may not be appropriate candidates for or willing to undergo open surgery. Nevertheless, degenerative LSS is the most common reason people over the age of 65 years undergo lumbar surgery (Deyo et al. 2010). The Superion device provides a minimally invasive alternative to open decompression surgery for many of these patients (Figure 1). Unlike direct decompression surgery, the Superion procedure leaves the epidural space intact, avoiding potential epidural scarring, adhesions and tethering around the dural sac and existing nerves that can cause subsequent problems and increase the complexity of future spine surgery (Nunley et al. 2016). In addition, because implantation of the Superion device does not

cause any anatomical disruption, the device can be easily removed or converted to laminectomy if symptoms persist or reoccur (Nunley et al. 2016).

Patients with severe stenosis or significant lumbar spine instability are not eligible for minimally invasive indirect decompression procedures because they often require significant bony excision or vertebral stabilisation that can only be achieved with open surgical techniques (Gala, Russo & Whang 2017).

Figure 1: Position of minimally invasive indirect spinal compression procedures in the continuum of care for degenerative LSS (Nunley et al. 2016)



Comparator

The comparator is direct decompression surgery, either open or minimally invasive. The proposed items will be offered in place of direct decompression surgery for patients with clinically and radiologically confirmed degenerative LSS at no more than two levels (from L1 to L5), with or without grade 1 spondylolisthesis, whose symptoms have not responded to at least six months of non-operative treatment.

Patients only become candidates for surgical treatment when they have undergone a trial of non-operative treatments for at least six months without symptom relief. The proposed device provides a minimally invasive treatment option that bridges the transition from a failed trial of conservative care to spine surgery. There are currently no alternatives to the proposed device that are minimally invasive but do not require surgery.

PASC confirmed that the comparator should be a weighted comparator of laminectomy with or without spinal fusion (non-inferiority).

PASC noted that the application indicated that spinal fusion surgery as a standalone procedure is only occasionally performed without prior decompression in Australia. PASC considered that the justification of whether or not spinal fusion surgery as a standalone procedure was an appropriate comparator should also be considered in the assessment report.

Rationale

Surgical treatment of patients with degenerative LSS varies depending upon the severity of the stenosis, the contribution of back pain and the presence of instability, among other factors (US FDA

2015). Conventional surgical options for patients with moderate symptoms of LSS include minimally invasive and open direct lumbar decompression techniques, direct decompression with non-fusion posterior stabilisation devices and decompression with spinal fusion (with or without instrumentation) (Deer et al. 2019; Kreiner et al. 2011).

Direct spinal decompression procedures include laminectomy (removal of a section of bone from one of the vertebrae) and discectomy (removal of a section of a damaged disc) to free trapped nerves while preserving stability in the spine. In many cases, a combination of these techniques is used (Australian Commission on Safety and Quality in Health Care 2017; Kreiner et al. 2011). Minimally invasive variations, such as uni- or bilateral laminotomy, spinous process-splitting laminectomy and percutaneous image-guided lumbar decompression, have also been developed (Costa et al. 2020; Deer et al. 2019; Deer et al. 2019; Kreiner et al. 2011). If the lumbar spine is unstable (degenerative spondylolisthesis >grade 1), fusion surgery, with or without instrumentation, is performed whereby two or more adjacent vertebrae are permanently joined together with a bone graft to immobilise the mobile spine segments. Direct decompression with non-fusion posterior stabilisation devices, such as the Coflex device (Surgalign, USA), is a less invasive alternative to fusion that utilises a device implanted during open decompression surgery to provide additional stability without the rigidity of an instrumented fusion, thus maintaining flexion of the lumbar vertebrae (Gala, Russo & Whang 2017).

The applicant nominated a weighted comparator of decompression with or without fusion surgery. This was based on the approach taken in MSAC Application 1099 and a recent study indicating that approximately 19% of patients with LSS in Australia undergo decompression plus fusion surgery—and the number is on the rise (Machado et al. 2017). However, this does not support the nominated comparator as the lack of detail in the study regarding associated diagnoses, such as spondylolisthesis or scoliosis, makes it unclear whether any of these patients would be eligible for the Superion procedure. The World Federation of Neurosurgical Societies guideline recommends decompression surgery alone for patients with LSS who have predominant leg pain and no sign or symptoms of instability, as well as for patients with LSS and stable spondylolisthesis. While unstable spondylolisthesis with symptoms may require fusion, there is no clear consensus regarding indications for fusion surgery in the presence of lumbar spine stenosis (Roitberg et al. 2020; Sharif et al. 2020). Thus, the decision to perform fusion in these patients is largely based on surgeon preference (Machado et al. 2017). Two recent systematic reviews found that concomitant degenerative spondylolisthesis (grade 1-2) does not influence the outcome of decompression surgery alone in patients with degenerative LSS, especially when a minimally invasive procedure is performed, and that the addition of fusion surgery does not result in better outcomes (Shen et al. 2018; Wang et al. 2019).

While the presence of unstable spondylolisthesis (\geq grade 2, see Table 1) may be an indication for fusion surgery, it is a contraindication for the Superion procedure. Therefore, decompression surgery alone is the most appropriate comparator for the Superion procedure. In the literature, the Superion device has been compared with laminectomy alone or the X-STOP device (Medtronic, Inc., USA), which was the comparator used in the US FDA pivotal trial for Superion (Gala, Russo & Whang 2017; Nunley et al. 2016; Patel, Nunley, et al. 2015; US FDA 2015). The X-STOP device was a minimally invasive stand-alone implant that shared the same indications as the Superion device and did not require open surgical decompression (Gala, Russo & Whang 2017). However, Medtronic voluntarily

discontinued X-STOP in 2015 due to a lack of efficacy in longer term follow up data (Gala, Russo & Whang 2017). An additional comparator would be decompression surgery with an interspinous decompression spacer, such as the Coflex implant, but these devices are not currently funded in Australia (see MSAC Application 1422).

Given that the choice of comparator should reflect not only the current published evidence, but also Australian clinical practice, PASC will need to consider whether, and to what degree, decompression plus fusion surgery is still occurring for the indicated patient population.

PASC noted the recent move away from traditional open laminectomy to more minimally invasive forms conducted by orthopaedic spinal surgeons and neurosurgeons. In addition, PASC noted that there is no clear consensus regarding the indications for fusion surgery in the presence of LSS. The presence of unstable spondylolisthesis is potentially a contraindication for the Superion procedure, in which case the use of a weighted comparator of open spinal decompression with or without spinal fusion may not be appropriate.

PASC noted that even though fusion is being performed in increasing numbers of patients in Australia, this does not constitute support for fusion in the proposed population as the factors contributing to these surgical decisions are unclear.

PASC noted the consultation feedback from the Spine Society of Australia (SSA), which suggested that the proposed patient group constitutes those with mild LSS who would not otherwise be considered for any type of surgical intervention, and who would have only received conservative treatment. Fusion is only considered for patients with significant spondylolisthesis (>25% slippage of one vertebral body on another), which is not an indication for the Superion device.

PASC noted that the SSA disagreed with the comparators in the application form. The SSA considered that: decompression by laminectomy (removal of a lumbar lamina) is uncommonly performed by modern spine surgeons in isolation but usually as part of reconstructive procedure as most patients have instability; and fusion surgery is for significant instability, which Superion would not be indicated.

PASC noted that continued conservative management may be a more appropriate comparator for the device given that the SSA considered that the patient group suggested as being eligible for the device is considered to have very mild LSS, which is not usually treated with surgery (see PASC outcome Number 8). The claim would then be one of superiority of the Superion device relative to conservative treatment. PASC considered that the justification of whether or not conservative management was an appropriate comparator should be considered in the assessment report.

Vertiflex®, Inc. (USA), the privately held company that originally developed and commercialised the Superion Indirect Decompression System, sponsored a multicentre randomised controlled trial comparing the device with open direct decompression over a five-year follow up period (ClinicalTrials.gov Identifier: NCT03048955). The study began recruiting in February 2017, but the US FDA and Vertiflex, Inc. closed the trial in 2019. Although a new post-marketing approval trial is currently in development, the reason for closing the first trial is unknown. PASC may wish to ask the applicant for further information regarding this abandoned trial.

The multicentre randomised controlled trial comparing the device with open direct decompression over a five-year follow up period (ClinicalTrials.gov Identifier: NCT03048955) was not completed because of difficulty recruiting patients willing to undergo the comparator procedure.

Outcomes

Patient relevant

The clinical claim is for non-inferiority to direct decompression surgery for patients with moderate degenerative LSS, with or without low grade spondylolisthesis, after an unsuccessful six-month trial of conservative management.

Primary effectiveness outcomes include the following:

- Disability and functional status measured by a back pain-specific scale, e.g., the Zurich Claudication Questionnaire (ZCQ), the Roland-Morris Low Back Pain and Disability Questionnaire or the Oswestry Disability Index (ODI)
 - *Note:* In the US FDA pivotal trial for Superion, a minimal clinically important change compared to baseline for ODI was defined as $\geq 15\%$ point improvement; for ZCQ, it was defined as improvement in at least two of three domains as follows: ≥ 0.5 point improvement in physical function; ≥ 0.5 point improvement in symptom severity; or a score of ≤ 2.5 points on patient satisfaction domain (US FDA 2015)
- Pain intensity measured by a visual analog or other pain scale
 - *Note:* Minimal clinically important change defined as ≥ 20 mm improvement in pain score in the US FDA pivotal trial (Patel, Nunley, et al. 2015)
- New or persistent worsened neurological deficit at the index level(s)
- Objective measure of walking capacity e.g., the 6-minute walking test or self-paced walking test

Secondary effectiveness outcomes include the following:

- Time to return to daily activities
- Patient satisfaction
- Health-related quality of life measured by a validated index, e.g., the Short Form (SF)-36 or European Organization for Research and Treatment of Cancer Core Quality of Life (EuroQol) Questionnaire

PASC noted the primary outcome in the US FDA pivotal trial was a complicated composite endpoint. Pain, disability and functional status are not necessarily easy to quantify in this patient group. It was noted that secondary outcomes, such as time to return to daily activities, satisfaction with treatment and impact on health-related quality of the life would be the most important considerations for patients.

PASC noted the SSA suggested that outcomes should include patient-assessed functional status.

Safety outcomes include the following:

- Device-related complications, e.g., rates of breakage, deformation, dislodgment, migration, subsidence and spinous process fracture

- Procedure-related complications, e.g., rates of infection, nerve root or spinal cord damage, worsening of symptoms, anaesthetic medication reactions, blood loss, pain and soft tissue damage
- Number of reoperations, removals or revisions
- Need for subsequent intervention, e.g., supplemental decompression or fixation at the index level(s), epidural injections, spinal cord stimulation or rhizotomy

Note: “Individual patient success”, the composite primary endpoint of the US FDA pivotal trial, included all of the following (US FDA 2015):

- Clinically significant improvement in the ZCQ (as defined above)
- No reoperations, removals, revisions, or supplemental fixation at the index level(s)
- No major implant or procedure-related complications (including dislodgement, migration, or deformation; new or persistent worsened neurological deficit at the index level; spinous process fractures, deep infection, death or other permanent device attributed disability)
- No clinically significant confounding treatments (no epidural injections, nerve block procedures at index level, spinal cord stimulators or rhizotomies).

PASC confirmed the appropriateness of the outcomes and minimal clinically important change stated in the PICO.

Healthcare system

The implantation of the Superior device is less invasive and expected to result in fewer complications than traditional surgical approaches. Therefore, introduction of the device is likely to change the way in which patients with moderate degenerative LSS are treated, particularly those who were previously ineligible for or unwilling to undergo open surgery.

Outcomes related to the healthcare system include the following:

- Number of patients eligible for the implant (utilisation)
- Device and procedure costs
- Cost of complications related to the procedure
- Cost of additional interventions related to device failure
- Follow-up utilisation of healthcare resources after successful device implantation (e.g., physiotherapy, chiropractic therapy, epidural steroid injections, diagnostics and medications)

Rationale

The reoperation rate within 10 years of lumbar decompressive surgery is estimated at 10-19% and the overall complication rate ranges from 12 to 29%, depending on comorbidity status (Costa et al. 2020; Parker et al. 2015; Wu & Cruz 2021). Among elderly patients, cardiopulmonary complications and stroke following decompressive surgery occur in approximately 2%—the mortality rate is 0.5% (Costa et al. 2020). Since degenerative LSS is predominantly a disease of the elderly, a demographic associated with high rates of comorbidities, there are likely to be important differences between the Superior procedure and direct decompression surgery for this population, particularly in terms of safety outcomes.

Current clinical management algorithm for identified population

The current clinical management algorithm for patients with moderate degenerative LSS, with or without degenerative spondylolisthesis, is provided in Figure 2.

Proposed clinical management algorithm for identified population

The current clinical management algorithm for patients with moderate degenerative LSS, with or without degenerative spondylolisthesis, who are eligible to receive the Superior device is provided in Figure 3.

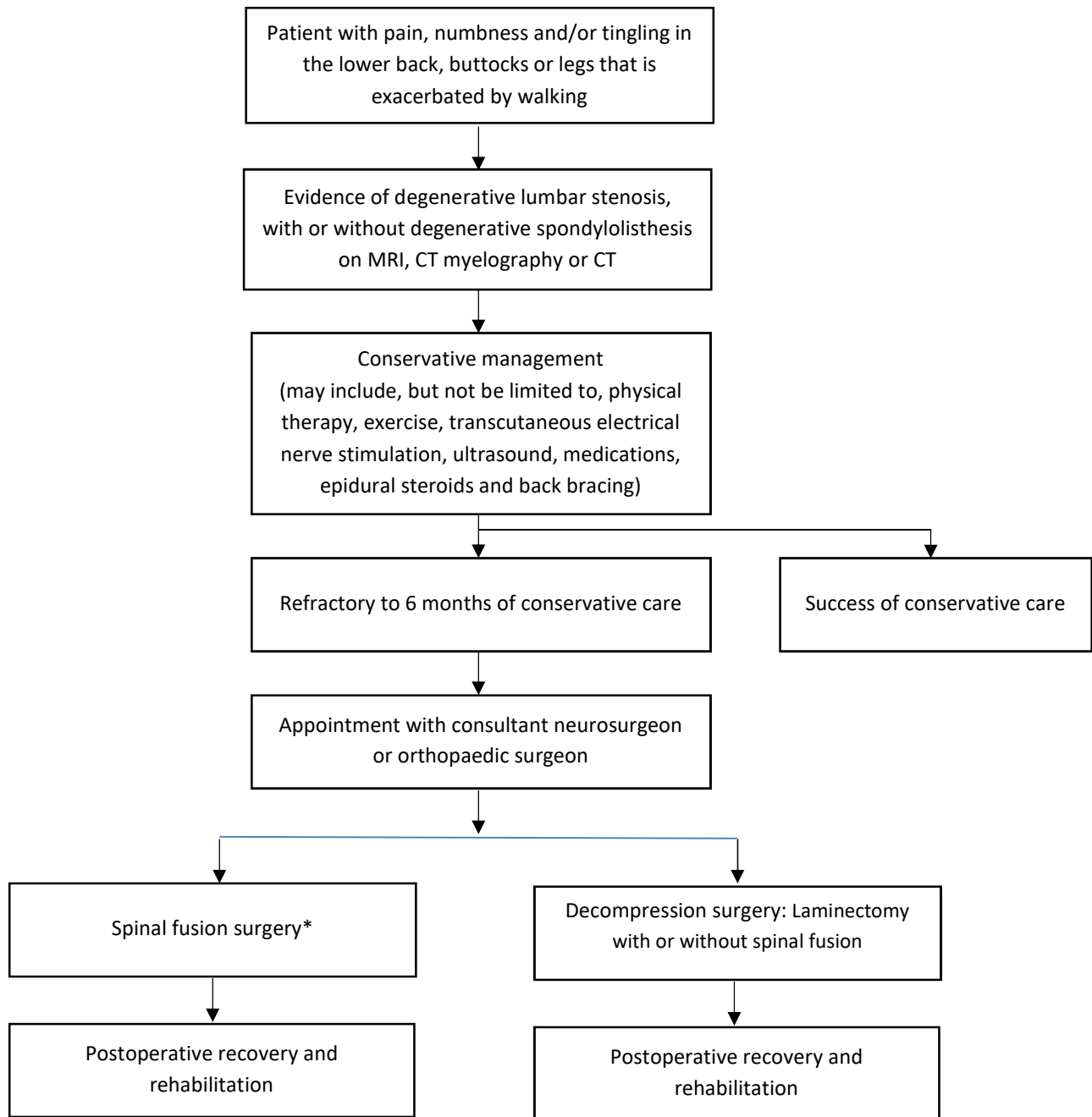


Figure 2: Current clinical management algorithm for patients with moderate degenerative LSS as defined in Table 1 (≤ 2 levels of spinal stenosis from L1-L5 \pm grade 1 spondylolisthesis)

Source: Adapted Post-PASC using Figure 1 from Attachment A of Application Form

* In Australia, fusion surgery is only occasionally performed without prior decompression

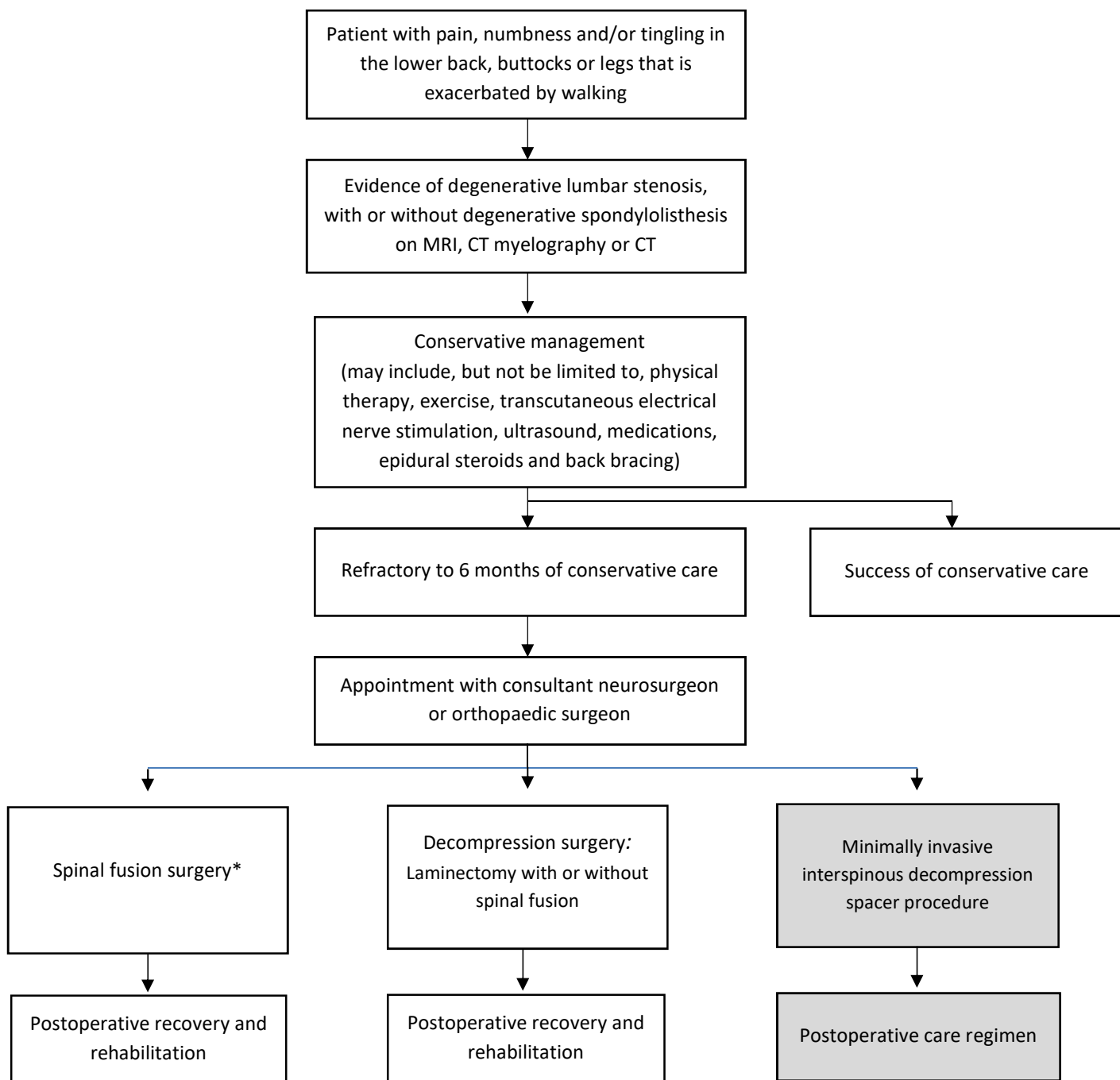


Figure 3: Proposed clinical management algorithm for patients with moderate degenerative LSS as defined in Table 1 (≤ 2 levels of spinal stenosis from L1-L5 \pm grade 1 spondylolisthesis)

Source: Adapted Post-PASC using Figure 1 from Attachment A of Application Form

* In Australia, fusion surgery is only occasionally performed without prior decompression

Proposed economic evaluation

The Superior device is expected to be non-inferior to decompression surgery for the nominated patient group. More invasive procedures are likely to be associated with a longer hospital stay, an increased risk of major complications and greater hospital and postoperative costs. Therefore, the main advantage of the Superior device relative to the current approach is providing equivalent effectiveness but with significantly fewer and less serious risks and complications, shorter hospitalisation time and a quicker return to usual activities. Thus, the most appropriate evaluation is a cost-effectiveness analysis (e.g. cost-utility analysis) to determine the costs of the device relative to its effectiveness in achieving these outcomes.

PASC noted that the perceived benefit of the Superior device was that it was less invasive than surgical alternatives and only requires a local anaesthetic. Imaging, most likely including MRI, would be required for patients receiving the device.

PASC considered it was unclear how many patients would be eligible for or require the procedure, what the device and procedure costs are and how many patients would require additional intervention after device implantation (either subsequent surgery or ongoing conservative care).

No changes were noted for the economic evaluation.

Proposed item descriptor

The fees estimated by the applicant for the proposed item descriptors for interspinous decompression spacer insertion (one or two levels) were based on MBS item 51020 (simple fixation of part of one vertebra or simple interspinous wiring between two adjacent vertebral levels). The population proposed is consistent with the ARTG indication listed for Superior, although PASC may wish to consider adding a more specific description of moderate LSS that aligns with the inclusion criteria used in the clinical trial of the Superior device (see Table 1).

The applicant has specified that the proposed service is not associated with any of the procedure codes for spinal decompression, thus precluding interspinous devices that require adjunctive surgical decompression (e.g., Coflex and the other interspinous decompression spacer devices registered on the ARTG). The total amount requested is less than the fee proposed for Coflex in MSAC Application 1422 because the procedure is less complex (Coflex requires adjunctive decompression). As per MSAC Application 1099, it is assumed that the proportion of patients treated would be the same for the comparator treatment (i.e., 69% at one level and 31% at two levels).

PASC noted that the SSA considered that the MBS item descriptor was not stringent enough to define patients with moderately severe LSS and that the inclusion criterion should be changed to patients with >50% spinal canal stenosis and a Zurich Claudication Questionnaire score of ≥ 2.5 to ensure that patients with moderate LSS are targeted, in line with previous surgical trials for this condition. However, although noting difficulties with the patient selection criteria PASC accepted the applicant's proposed population- but considered that it (and the proposed item descriptor) would need to be adequately justified in the assessment phase.

Category 3 – THERAPEUTIC PROCEDURES

MINIMALLY INVASIVE INTERSPINOUS DECOMPRESSION SPACER, insertion, removal or replacement of, to alleviate pain in patients with:

- Moderate lumbar spinal stenosis - one lumbar motion segment.
- After failure of conservative management for at least 6 months.
- Moderately severe functional impairment with symptoms exacerbated in extension and relieved in flexion.
- With or without low-grade spondylolisthesis

Not being a service associated with a service to which item 51011, 51012, 51013, 51014 or 51015 applies

Multiple Services Rule (Anaes.) (Assist.)

Fee: \$789.35

Category 3 – THERAPEUTIC PROCEDURES

MINIMALLY INVASIVE INTERSPINOUS DECOMPRESSION SPACER, insertion, removal or replacement of, to alleviate pain in patients with:

- Moderate lumbar spinal stenosis - two lumbar motion segments.
- After failure of conservative management for at least 6 months.
- Moderately severe functional impairment with symptoms exacerbated in extension and relieved in flexion.
- With or without low-grade spondylolisthesis

Not being a service associated with a service to which item 51011, 51012, 51013, 51014 or 51015 applies

Multiple Services Rule (Anaes.) (Assist.)

Fee: \$1,184.03

[Consultation feedback](#)

The Department received targeted consultation responses from the Neuromodulation Society of Australia and New Zealand (NSANZ) and the Spine Society of Australia (SSA), and also two responses from device manufacturers to the open consultation process on this application.

The targeted consultation response from the NSANZ was generally supportive of the application.

The SSA raised several concerns regarding the proposed intervention. The SSA considered the proposed population too broad, as it includes patients with mild and tolerable LSS who do not warrant invasive interventions and would benefit from conservative care. The SSA considered that the proposed comparators were not appropriate to the proposed intervention. The SSA suggested to include patient assessed functional status in the outcomes and queried whether sufficient evidence was currently available to demonstrate the benefit of the proposed intervention.

The open consultation responses from device manufacturers supported the application and suggested that the proposed medical service should be device agnostic.

PASC noted the targeted consultation feedback from the Spine Society of Australia (SSA), which suggested that the proposed patient group constitutes those with mild LSS who would not otherwise be considered for any type of surgical intervention, and who would have only received conservative

treatment. Fusion is only considered for patients with significant spondylolisthesis (>25% slippage of one vertebral body on another), which is not an indication for the Superior device.

PASC noted that the SSA suggested that outcomes should include patient-assessed functional status.

PASC noted that the SSA considered that the MBS item descriptor was not stringent enough to define patients with moderately severe LSS and that the inclusion criterion should be changed to patients with >50% spinal canal stenosis and a Zurich Claudication Questionnaire score of ≥ 2.5 to ensure that patients with moderate LSS are targeted, in line with previous surgical trials for this condition. However, although noting difficulties with the patient selection criteria PASC accepted the applicant's proposed population- but considered that it (and the proposed item descriptor) would need to be adequately justified in the assessment phase.

PASC noted the consultation feedback received from several device manufacturers providing support for the application. The feedback also considered that the evidence review should be broad enough (not device/brand specific) to ensure that all currently registered and 'near market' comparator devices are included.

PASC noted that the proposed medical service is for the implantation of any minimally invasive interspinous decompression spacers that meets the item descriptor, which is not restricted to any device such as the Superior.

Next steps

PASC advised that, upon ratification of the post-PASC PICO, the application can proceed to the Evaluation Sub-Committee (ESC) stage of the MSAC process.

PASC noted the applicant has elected to progress its application as an ADAR (applicant developed assessment report).

Applicant Comments on the PICO Confirmation

Intervention

The applicant agreed that "a weighted comparator of laminectomy with or without spinal fusion (non-inferiority)" is appropriate.

Current and proposed clinical management algorithm for identified population

The applicant advised that the Superior device is implanted under conscious sedation or local anaesthesia. The procedure does not require an MRI. The implant can be surgically placed under either total fluoroscopic guidance or with direct visualisation.

Proposed economic evaluation

Based on the discussion at the PASC meeting and the content of the PICO document the applicant believes that conservative care is also a relevant comparator for Superior.

References

- Ahmed, SI, Javed, G, Bareeqa, SB, Shah, A, Zubair, M, Avedia, RF, Rahman, N, Samar, SS & Aziz, K 2018, 'Comparison of decompression alone versus decompression with fusion for stenotic lumbar spine: A systematic review and meta-analysis', *Cureus*, vol. 10, no. 8, p. e3135.
- Andreisek, G, Hodler, J & Steurer, J 2011, 'Uncertainties in the diagnosis of lumbar spinal stenosis', *Radiology*, vol. 261, no. 3, pp. 681-4.
- Andreisek, G, Imhof, M, Wertli, M, Winklhofer, S, Pfirrmann, CW, Hodler, J, Steurer, J for the Lumbar Spinal Stenosis Outcome Study Working Group Zurich 2013, 'A systematic review of semiquantitative and qualitative radiologic criteria for the diagnosis of lumbar spinal stenosis', *Am J Roentgenol*, vol. 201, no. 5, pp. W735-46.
- Australian Commission on Safety and Quality in Health Care 2017, *The second Australian atlas of healthcare variation*, Australian Commission on Safety and Quality in Health Care, viewed 28 February 2021, <<https://www.safetyandquality.gov.au/our-work/healthcare-variation/atlas-2017>>.
- Australian Government Department of Health and Ageing 2008, *Report on the audit of health workforce in rural and regional Australia*, Australian Government Department of Health and Ageing, viewed 28 February 2021, <<https://www1.health.gov.au/internet/publications/publishing.nsf/Content/work-res-ruraud-toc>>.
- Australian Institute of Health and Welfare (AIHW) 2018, *Older Australia at a glance*, AIHW, viewed 28 February 2021, <<https://www.aihw.gov.au/reports/older-people/older-australia-at-a-glance/contents/demographics-of-older-australians/australia-s-changing-age-gender-profile>>.
- Cairns, K, Deer, T, Sayed, D, van Noort, K & Liang, K 2019, 'Cost-effectiveness and safety of interspinous process decompression (Superion)', *Pain Med*, vol. 20, no. Suppl 2, pp. S2-S8.
- Chen, LH, Ferreira, PR, Beckenkamp PL, & Ferreira, M 2019, 'Comparative efficacy and safety of surgical and invasive treatments for adults with degenerative lumbar spinal stenosis: protocol for a network meta-analysis and systematic review', *BMJ Open*, vol. 9, no. 4, p. e024752.
- Costa, F, Alves, OL, Anania, CD, Zileli, M & Fornari, M 2020, 'Decompressive surgery for lumbar spinal stenosis: WFNS Spine Committee recommendations', *World Neurosurg X*, vol. 7, p. 100076.
- Deer, T, Sayed, D, Michels, J, Josephson, Y, Li, S & Calodney, AK 2019, 'A review of lumbar spinal stenosis with intermittent neurogenic claudication: Disease and diagnosis', *Pain Med*, vol. 20, no. Suppl 2, pp. S32-S44.
- Deer, TR, Grider, JS, Pope, JE, Falowski, S, Lamer, TJ, Calodney, A, Provenzano, DA, Sayed, D, Lee, E, Wahezi, SE, Kim, C, Hunter, C, Gupta, M, Benyamin, R, Chopko, B, Demesmin, D, Diwan, S, Gharibo, C, Kapural, L, Kloth, D, Klagges, BD, Harned, M, Simopoulos, T, McJunkin, T, Carlson, JD, Rosenquist, RW, Lubenow, TR & Mekhail, N 2019, 'The MIST Guidelines: The Lumbar Spinal Stenosis Consensus Group Guidelines for Minimally Invasive Spine Treatment', *Pain Pract*, vol. 19, no. 3, pp. 250-74.
- Deyo, RA, Mirza, SK, Martin, BI, Kreuter, W, Goodman, DC & Jarvik, JG 2010, 'Trends, major medical complications, and charges associated with surgery for lumbar spinal stenosis in older adults', *JAMA*, vol. 303, no. 13, pp. 1259-65.

Fornari, M, Robertson, SC, Pereira, P, Zileli, M, Anania, CD, Ferreira, A, Ferrari, S, Gatti, R & Costa, F 2020, 'Conservative treatment and percutaneous pain relief techniques in patients with lumbar spinal stenosis: WFNS Spine Committee recommendations', *World Neurosurg X*, vol. 7, p. 100079.

Gala, RJ, Russo, GS & Whang, PG 2017, 'Interspinous implants to treat spinal stenosis', *Curr Rev Musculoskelet Med*, vol. 10, no. 2, pp. 182-8.

Ishimoto, Y, Yoshimura, N, Muraki, S, Yamada, H, Nagata, K, Hashizume, H, Takiguchi, N, Minamide, A, Oka, H, Kawaguchi, H, Nakamura, K, Akune, T & Yoshida, M 2013, 'Associations between radiographic lumbar spinal stenosis and clinical symptoms in the general population: the Wakayama Spine Study', *Osteoarthritis Cartilage*, vol. 21, no. 6, pp. 783-8.

Jensen, RK, Jensen, TS, Koes, B & Hartvigsen, J 2020, 'Prevalence of lumbar spinal stenosis in general and clinical populations: A systematic review and meta-analysis', *Eur Spine J*, vol. 29, no. 9, pp. 2143-63.

Kalichman, L, Cole, R, Kim, DH, Li, L, Suri, P, Guermazi, A & Hunter, DJ 2009, 'Spinal stenosis prevalence and association with symptoms: the Framingham Study', *Spine J*, vol. 9, no. 7, pp. 545-50.

Kreiner, DS, Shaffer, WO, Baisden, JL, Gilbert, TJ, Summers, JT, Toton, JF, Hwang, SW, Mendel, RC & Reitman, CA 2011, *Diagnosis and treatment of degenerative lumbar spinal stenosis (update)*, North American Spine Society, viewed 28 February 2021, <<https://www.spine.org/Portals/0/assets/downloads/ResearchClinicalCare/Guidelines/LumbarStenosis.pdf>>.

Kuittinen, P, Sipola, P, Saari, T, Aalto, TJ, Sinikallio, S, Savolainen, S, Kroger, H, Turunen, V, Leinonen, V & Airaksinen, O 2014, 'Visually assessed severity of lumbar spinal canal stenosis is paradoxically associated with leg pain and objective walking ability', *BMC Musculoskelet Disord*, vol. 15, p. 348.

Lohman, CM, Tallroth, K, Kettunen, JA & Lindgren, KA 2006, 'Comparison of radiologic signs and clinical symptoms of spinal stenosis', *Spine (Phila Pa 1976)*, vol. 31, no. 16, pp. 1834-40.

Machado, GC, Maher, CG, Ferreira, PH, Harris, IA, Deyo, RA, McKay, D, Li, Q & Ferreira, ML 2017, 'Trends, complications, and costs for hospital admission and surgery for lumbar spinal stenosis', *Spine (Phila Pa 1976)*, vol. 42, no. 22, pp. 1737-43.

Munakomi, S, Foris, LA & Varacallo, M 2021, 'Spinal stenosis and neurogenic claudication', in *StatPearls*, viewed 28 February 2021, <<https://www.ncbi.nlm.nih.gov/pubmed/28613622>>.

Nunley, PD, Shamie, AN, Blumenthal, SL, Orndorff, D, Block, JE & Geisler, FH 2016, 'Interspinous process decompression: expanding treatment options for lumbar spinal stenosis', *Biomed Res Int*, vol. 2016, p. 3267307.

Otani, K, Kikuchi, S, Yabuki, S, Igarashi, T, Nikaido, T, Watanabe, K & Konno, S 2013, 'Lumbar spinal stenosis has a negative impact on quality of life compared with other comorbidities: an epidemiological cross-sectional study of 1862 community-dwelling individuals', *ScientificWorldJournal*, vol. 2013, p. 590652.

Overvest, GM, Jacobs, W, Vleggeert-Lankamp, C, Thomé, C, Gunzburg, R & Peul, W 2015, 'Effectiveness of posterior decompression techniques compared with conventional laminectomy for lumbar stenosis', *Cochrane Database Syst Rev*, no. 3, p. CD010036.

Parker, SL, Anderson, LH, Nelson, T & Patel, VV 2015, 'Cost-effectiveness of three treatment strategies for lumbar spinal stenosis: Conservative care, laminectomy, and the Superior interspinous spacer', *Int J Spine Surg*, vol. 9, p. 28.

Patel, VV, Nunley, PD, Whang, PG, Haley, TR, Bradley, WD, Davis, RP, Block, JE & Geisler, FH 2015, 'Superion(®) InterSpinous Spacer for treatment of moderate degenerative lumbar spinal stenosis: durable three-year results of a randomized controlled trial', *J Pain Res*, vol. 8, pp. 657-62.

Patel, VV, Whang, PG, Haley, TR, Bradley, WD, Nunley, PD, Davis, RP, Miller, LE, Block, JE & Geisler, FH 2015, 'Superion interspinous process spacer for intermittent neurogenic claudication secondary to moderate lumbar spinal stenosis: two-year results from a randomized controlled FDA-IDE pivotal trial', *Spine (Phila Pa 1976)*, vol. 40, no. 5, pp. 275-82.

Poetscher, AW, Gentil, AF, Ferretti, M & Lenza, M 2018, 'Interspinous process devices for treatment of degenerative lumbar spine stenosis: A systematic review and meta-analysis', *PLoS One*, vol. 13, no. 7, p. e0199623.

Raja, A, Hoang, S, Patel, P & Mesfin, FB 2021, 'Spinal Stenosis', in *StatPearls*, viewed 28 February 2021, <<https://www.ncbi.nlm.nih.gov/pubmed/28723018>>.

Roitberg, B, Zileli, M, Sharif, S, Anania, C, Fornari, M & Costa, F 2020, 'Mobility-preserving surgery for lumbar spinal stenosis: WFNS Spine Committee recommendations', *World Neurosurg X*, vol. 7, p. 100078.

Sharif, S, Shaikh, Y, Bajamal, AH, Costa, F & Zileli, M 2020, 'Fusion surgery for lumbar spinal stenosis: WFNS Spine Committee recommendations', *World Neurosurg X*, vol. 7, p. 100077.

Shen, J, Xu, S, Xu, S, Ye, S & Hao, J 2018, 'Fusion or not for degenerative lumbar spinal stenosis: A meta-analysis and systematic review', *Pain Physician*, vol. 21, no. 1, pp. 1-8.

United States Food and Drug Administration (US FDA) 2005, *PMA P040001: FDA Summary of safety and effectiveness data*, US FDA, viewed 28 February 2021, <https://www.accessdata.fda.gov/cdrh_docs/pdf4/P040001b.pdf>.

US FDA 2015, *PMA P140004: FDA Summary of safety and effectiveness data*, US FDA, viewed 28 February 2021, <https://www.accessdata.fda.gov/cdrh_docs/pdf14/p140004b.pdf>.

VertiFlex®, Incorporated 2015, *Instructions for use Superion® Interspinous Spacer*, VertiFlex®, Incorporated, viewed 28 February 2021, <https://www.accessdata.fda.gov/cdrh_docs/pdf14/P140004D.pdf>.

Wang, M, Luo, XJ, Ye, YJ & Zhang, Z 2019, 'Does concomitant degenerative spondylolisthesis influence the outcome of decompression alone in degenerative lumbar spinal stenosis? A meta-analysis of comparative studies', *World Neurosurg*, vol. 123, pp. 226-38.

Wu, L & Cruz, R 2021, 'Lumbar spinal stenosis', in *StatPearls*, viewed 28 February 2021, <<https://www.ncbi.nlm.nih.gov/pubmed/30285388>>.

Yabuki, S, Fukumori, N, Takegami, M, Onishi, Y, Otani, K, Sekiguchi, M, Wakita, T, Kikuchi, S, Fukuhara, S & Konno, S 2013, 'Prevalence of lumbar spinal stenosis, using the diagnostic support tool, and correlated factors in Japan: a population-based study', *J Orthop Sci*, vol. 18, no. 6, pp. 893-900.

Zileli, M, Crostelli, M, Grimaldi, M, Mazza, O, Anania, C, Fornari, M & Costa, F 2020, 'Natural course and diagnosis of lumbar spinal stenosis: WFNS Spine Committee recommendations', *World Neurosurg X*, vol. 7, p. 100073.