

---

1392

Final protocol to guide the assessment of Corneal Collagen Cross Linking (CXL) for patients with corneal ectatic disorders who are at risk of progression or showing evidence of progression.

---

April 2015

---

## Table of Contents

<b>MSAC and PASC</b> .....	<b>3</b>
Purpose of this document .....	3
<b>Purpose of application</b> .....	<b>4</b>
<b>Intervention</b> .....	<b>4</b>
Description .....	4
Administration, dose, frequency of administration, duration of treatment .....	5
Co-administered interventions .....	5
<b>Background</b> .....	<b>6</b>
Current arrangements for public reimbursement .....	6
Regulatory status .....	6
<b>Patient population</b> .....	<b>6</b>
Clinical place for proposed intervention .....	7
<b>Comparator</b> .....	<b>8</b>
<b>Proposed MBS listing</b> .....	<b>8</b>
<b>Clinical claim</b> .....	<b>9</b>
<b>Outcomes and health care resources affected by introduction of proposed intervention</b> .....	<b>10</b>
Outcomes .....	10
<b>Proposed structure of economic evaluation (decision-analytic)</b> .....	<b>11</b>
<b>References</b> .....	<b>11</b>

## MSAC and PASC

The Medical Services Advisory Committee (MSAC) is an independent expert committee appointed by the Minister for Health (the Minister) to strengthen the role of evidence in health financing decisions in Australia. MSAC advises the Minister on the evidence relating to the safety, effectiveness, and cost-effectiveness of new and existing medical technologies and procedures and under what circumstances public funding should be supported.

The Protocol Advisory Sub-Committee (PASC) is a standing sub-committee of MSAC. Its primary objective is the determination of protocols to guide clinical and economic assessments of medical interventions proposed for public funding.

### Purpose of this document

This document is intended to provide a draft decision analytic protocol that will be used to guide the assessment of an intervention for a particular population of patients. The draft protocol will be finalised after inviting relevant stakeholders to provide input to the protocol. The final protocol will provide the basis for the assessment of the intervention.

The protocol guiding the assessment of the health intervention has been developed using the widely accepted "PICO" approach. The PICO approach involves a clear articulation of the following aspects of the research question that the assessment is intended to answer:

- P**atients – specification of the characteristics of the patients in whom the intervention is to be considered for use;
- I**ntervention – specification of the proposed intervention
- C**omparator – specification of the therapy most likely to be replaced by the proposed intervention
- O**utcomes – specification of the health outcomes and the healthcare resources likely to be affected by the introduction of the proposed intervention

## Purpose of application

A proposal for an application requesting MBS listing of Corneal Collagen Cross Linking for patients with corneal ectatic disorders with progression of the disease or at risk of progression of the disease<sup>1</sup>. was received from Dr Nicholas Downie on behalf of the Royal Australian and New Zealand College of Ophthalmologists by the Department of Health and Ageing in October 2014.

## Intervention

### Description

Corneal ectatic disorders are a group of eye disorders characterised by thinning of the cornea, which include: keratoconus, posterior keratoconus, keratoglobus<sup>2</sup>, pellucid marginal degeneration, and Terrien's marginal degeneration. The most common of these disorders, comprising approximately 90% of patients, is keratoconus, which has an estimated prevalence 1 in 2000<sup>3</sup>, i.e. 0.05% of general population (Rabinowitz, 1998; Wollensack 2003), which given Australia's population of 23 million, would translate into 11,500 patients with the disease. The applicant advises that in some ethnic groups, the prevalence will be higher. Jinabhai et al (2010) report that incidence and prevalence of pellucid marginal degeneration is unknown, but it is both rare and much less common than keratoconus; the Applicant confirms this is the case in Australia. Other corneal ectatic disorders, including posterior keratoconus or keratoglobus, are even more rarely reported.

In general, 90% of patients with corneal ectatic disorders are treated with glasses and rigid contact lenses, with corneal transplants (keratoplasty) as the main surgical option for those patients who are unsuitable or inadequately managed by contact lenses (Rabinowitz, 1998; Brown 2014). Because these techniques do not treat the underlying cause of corneal ectasia (bulging) but rather, only correct the refractive errors of corneal ectatic disorders, a new technique of corneal collagen crosslinking (CXL) has been developed. Several different CXL protocols have been described in the literature, including Epithelium Off/Dresden protocol, transepithelial cross-linking and accelerated cross-linking. CXL counteracts the progression of keratoconus through counteracting the progressive corneal thinning. In CXL, the collagen cross-linking is effected by the use of a photosensitiser riboflavin (0.1% solution), and UVA light source. The collagen cross-linking introduces additional bonding between collagen molecules, which stiffens the cornea, and reduces the risk of progression of the disease (Raiskup-Wolf, 2008).

---

<sup>1</sup> The patient population was initially restricted to patients with keratoconus, however, it was broadened to corneal ectatic diseases as a result of public consultation.

<sup>2</sup> The Applicant advises that there are two forms of keratoglobus: congenital and acquired. The congenital form is associated with syndromes such as: Rubenstein-Taybi, Ehlers Danlos, and Leber's congenital amaurosis. These forms are not progressive; corneal collagen cross-linking would be inappropriate for them. The acquired form of keratoglobus is associated with vernal conjunctivitis and eye rubbing, and corneal collagen cross-linking may be appropriate.

<sup>3</sup> Higher prevalence has been reported elsewhere in the literature. E.g., Jonas et al (2009) report prevalence of 2.3% in India, while Hashemi et al (2013) report prevalence of 3.3% in Iran. The discrepancies in prevalence estimates may be due to improvements in diagnostic technologies, as well as due to difference in prevalence among different ethnic groups.

### **Administration, dose, frequency of administration, duration of treatment**

In CXL, the patient is placed under an operating microscope and anaesthetic (topical) is applied. Usually, oral sedation is required. Depending on the details of the CXL protocol being followed, the corneal epithelium is removed, and 0.1% riboflavin solution is applied to the cornea for 30 minutes. After 30 minutes, the cornea is measured using ultrasonic pachymetry in most cases; with partial coherence laser interferometry if necessary. If thickening is inadequate, the exposure to riboflavin solution is continued until the cornea thickens. Once the cornea thickens, a UVA light source (400-320 nm) is applied to the cornea and riboflavin is applied for an additional 30 minutes. A bandage contact lens is subsequently applied in order to reduce pain in the post-operative period, and treatment with topical antibiotics and steroids is given postoperatively. The applicant advises that the corneal epithelium typically heals in 3-4 days.

The CXL procedure can be performed in day surgery facilities or other facilities that have adequate air handling systems and sterile conditions.

The intervention should be provided by an ophthalmologist; many will have additional training and subspecialty in corneal surgery.

### **Co-administered interventions**

Co-administered interventions include:

- Testing to establish progression of corneal ectatic disorder, as measured by: keratometry (using keratometer), change in refraction (measured by retinoscopy or an autorefractor), changes in topography (measured using a topographer or a scheimpflug camera), changes in pachymetry (assessed with a pachymeter or partial coherence laser interferometry), or through the clinical signs of keratoconus (e.g. oil drop reflex, haemosiderin rings, or increased corneal nerves; most clinical signs are assessed using a slit lamp microscope); decrease in best corrected acuity may also be used. The history, clinical features, and topographic features are used in differentiating the disorders.
- anaesthetic: usually topical, although general anaesthetic is used in some patient groups – e.g. very young children or intellectually disabled patients. The topical anaesthetics most commonly used are alcaine and oxybuprocaine
- isotonic or hypotonic 0.1% riboflavin solution
- UVA light source: commonly used are Emagin Pty Ltd, Designs for Vision Aust Pty Ltd, Optos Australia Pty Ltd.
- bandage contact lens: any high water content high oxygen transmission soft contact lens could be used, e.g. Bausch & Lomb Purevision lenses
- topical antibiotics: most commonly used antibiotic drop is chloramphenicol but other antibiotics may be used (e.g. in case where infection is developing).
- steroids: e.g., fluoromethalone, prednisolone, and dexamethasone.

## Background

### Current arrangements for public reimbursement

The corneal collagen cross-linking procedure is not presently MBS-listed; the applicant is seeking its listing on the MBS. The Department of Health advises that in the absence of public funding, Australian patients are presently being charged between \$1200 and \$6000 for the procedure, although the procedure is also carried out in some public hospitals (e.g. the Royal Victorian Eye and Ear Hospital carries out two cases per week). Public Consultation submissions from consumers indicate that the current fees charged average \$2000-\$3000 per eye, or \$4000-\$6000 for both eyes.

Progression in corneal ectatic disorders such as keratoconus is established by progressive steepening of the cornea, as measured by: keratometry (using keratometer), change in refraction (measured by retinoscopy or an autorefractor), changes in topography (measured using a topographer or a scheimpflug camera), changes in pachymetry (assessed with a pachymeter or partial coherence laser interferometry), or through the clinical signs (e.g. oil drop reflex, haemosiderin rings, or increased corneal nerves; most clinical signs are assessed using a slit lamp microscope). A decrease in best corrected acuity is also a useful measure for identifying keratoconus progression. All of these measures are presently in use in Australia, although they are not MBS-listed. (The history, clinical features, and topographic features are used in differentiating between the corneal ectatic disorders themselves).

Topical anaesthetics typically used in this procedure are alcaine and oxybuprocaine; these are not PBS-listed.

The isotonic or hypotonic 0.1% riboflavin solution is TGA approved but it is not PBS-listed. It requires the completion of a special access form which is submitted to the Department of Health.

Bandage contact lenses are not listed on the MBS.

Topical antibiotic most commonly used is chloramphenicol, but other antibiotics may be used (e.g. in case where infection is developing). Most are PBS-listed.

Steroids used include, for example, fluoromethalone, prednisolone, and dexamethasone. All are PBS-listed.

### Regulatory status

Applicant advises that the UVA light source devices in common use in Australia for the CXL procedure are the following, TGA-approved devices: Emagin Pty Ltd (ARTG # 142260), Designs for Vision Aust Pty Ltd (ARTG # 182411) and Optos Australia Pty Ltd (ARTG # 162158).

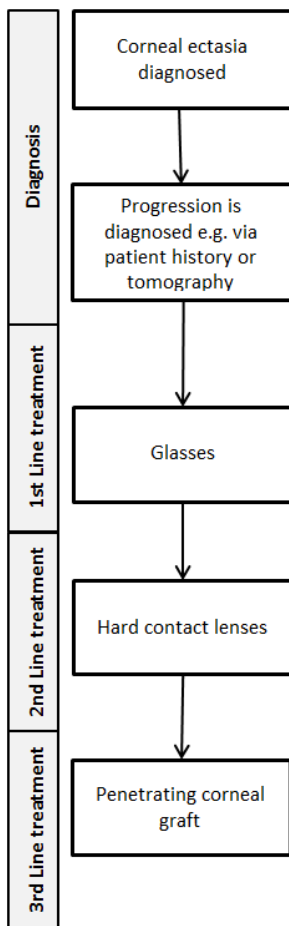
### Patient population

CXL will be used in patients with corneal ectatic disorders with evidence of progression of the disease.

### Clinical place for proposed intervention

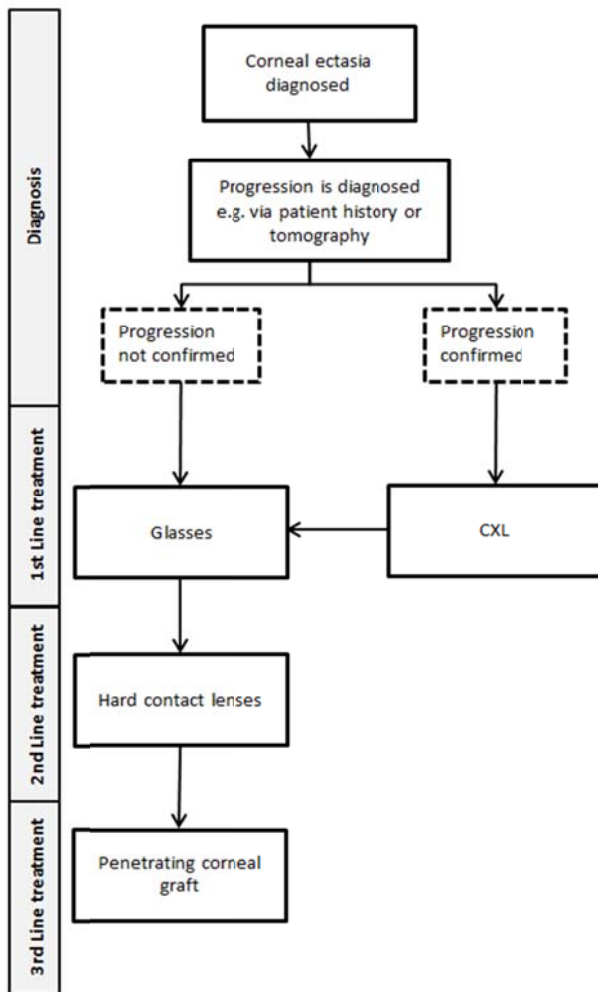
The current approach to treating patients with corneal ectatic disorders involves, in the first instance, attempting to improve the patient's vision with glasses, if possible. If the condition progresses, and the glasses no longer improve the patient's vision, hard contact lenses are fitted. If the lenses cannot be fitted, or are unsuccessful, patients undergo penetrating corneal graft. Some patients currently access corneal collagen cross-linking as an alternative to corneal grafting by self-funding the procedure.

Figure 1: Current clinical management algorithm without the proposed intervention



Under the proposed clinical management algorithm, CXL would be used as a first line treatment once there is evidence of progression, regardless of whether glasses or contact lenses have been tried.

Figure 2: Clinical management algorithm with the proposed intervention



N.B. the proposed treatment pathway utilises CXL as a preventative treatment (intending to halt the progress of the disease early).

## Comparator

The nominated comparator for the corneal collagen cross-linking procedure for patients with corneal ectatic disorders is the current treatment pathway, as advised by PASC.

## Proposed MBS listing

The proposed MBS item descriptor for corneal collagen cross-linking is indicated in Table 1, below

Due to the high risk of rapid progression in juveniles, specialists use additional measures to determine evidence of progression in the absence of progression from patient history – those additional measures include posterior elevation data and objective documented progression at a subclinical level. However, as it is also important to avoid over-servicing patients who are older than 25, in whom the progression of the disease is typically much slower, patient history would be the appropriate level of evidence to show progression. Therefore, the MBS item descriptor contains



explanatory notes differentiating between the evidence required for patients younger than 25, and older than 25.

**Table 1: Proposed MBS item descriptor for corneal collagen cross-linking**

Category 3 – Therapeutic Procedures – Ophthalmology Services
MBS [item number]
Corneal Collagen Cross Linking, for patients with corneal ectatic disorders with evidence of progression. Fee: \$1500 [Applicant-proposed fee]. (PASC suggests that the appropriate MBS fee could be between the cost of cataract surgery and corneal transplant (\$900-\$1300)) (Based on submissions fee may need to be revised upwards to >\$2000).
(Anaes.)
Explanatory Note:
Evidence of progression in patients over the age of twenty five is determined by the patient history including an objective change in tomography or refraction over time.
Evidence of progression in patients aged twenty five years or younger is determined by patient history including an objective change in tomography or refraction over time and/or posterior elevation data and objective documented progression at a subclinical level.

The applicant proposed fee is \$1500. PASC has suggested a fee of \$900-\$1300 would be appropriate, as that fee is between the cost of cataract surgery and corneal transplant. During the public consultation, consumers advised that currently, they are being charged between \$2000-3000 per eye (\$4000-\$6000 for both eyes). The fee for this procedure should ideally conform to MSAC’s preference for input-based fee estimates. The fee nominated in the evidence assessment will also need to be supported with evidence of cost-effectiveness and acceptable financial impact to the MBS.

### Clinical claim

The claim is that corneal collagen cross-linking is safer and more cost-effective than the current treatment pathway. In the event that the claims of superior clinical efficacy and safety are supported by the literature, a cost-utility or cost-effectiveness economic analysis would be appropriate (Table 2).

**Table 2: Classification of an intervention for determination of economic evaluation to be presented**

		Comparative effectiveness versus comparator					
		Superior		Non-inferior	Inferior		
Comparative safety versus comparator	Superior	CEA/CUA		CEA/CUA	Net clinical benefit	CEA/CUA	
					Neutral benefit	CEA/CUA*	
					Net harms	None^	
	Non-inferior	CEA/CUA		CEA/CUA*	None^		
		Inferior	Net clinical benefit		CEA/CUA	None^	None^
			Neutral benefit		CEA/CUA*		
Net harms	None^						

Abbreviations: CEA = cost-effectiveness analysis; CUA = cost-utility analysis

\* May be reduced to cost-minimisation analysis. Cost-minimisation analysis should only be presented when the proposed service has been indisputably demonstrated to be no worse than its main comparator(s) in terms of both effectiveness and safety, so the difference between the service and the appropriate comparator can be reduced to a comparison of costs. In most cases, there will be some uncertainty around such a conclusion (i.e., the conclusion is often not indisputable). Therefore, when an assessment concludes that an intervention was no worse than a comparator, an

assessment of the uncertainty around this conclusion should be provided by presentation of cost-effectiveness and/or cost-utility analyses.

<sup>^</sup> No economic evaluation needs to be presented; MSAC is unlikely to recommend government subsidy of this intervention

## Outcomes and health care resources affected by introduction of proposed intervention

### Outcomes

This assessment will consider:

- Safety of the corneal collagen cross-linking procedure
  - Corneal oedema
  - Postoperative corneal haze
  - Stromal haze
  - Diffuse lamellar keratitis
  - Reactivation of herpetic keratitis
  - Change in endothelial cell density
  - Postoperative infection
  - Damage to the cornea
- Effectiveness of the corneal collagen cross-linking procedure
  - Decreased risk of progression to transplantation
  - Improvement in visual acuity
  - Spherical equivalent refractive error improvement
  - Reduction of visual losses
  - Quality adjusted-life years
- Cost-effectiveness of the corneal collagen cross-linking procedure

## Proposed structure of economic evaluation (decision-analytic)

Table 3: Summary of extended PICO to define research question that assessment will investigate

Patients	Intervention	Comparator	Outcomes to be assessed
Patients with corneal ectatic disorders with evidence of progression	Corneal collagen cross-linking	Current treatment pathway.	<p><u>Safety</u></p> <ul style="list-style-type: none"> <li>• Corneal oedema</li> <li>• Postoperative corneal haze</li> <li>• Stromal haze</li> <li>• Diffuse lamellar keratitis</li> <li>• Reactivation of herpetic keratitis</li> <li>• Change in endothelial cell density</li> <li>• Postoperative infection</li> <li>• Damage to the cornea</li> </ul> <p><u>Effectiveness</u></p> <ul style="list-style-type: none"> <li>• Decreased risk of progression to transplantation</li> <li>• Improvement in visual acuity</li> <li>• Spherical equivalent refractive error improvement</li> <li>• Reduction of visual losses</li> <li>• Quality adjusted-life years</li> <li>• Improvement of vision</li> </ul> <p><u>Cost-effectiveness</u></p>

## References

- Brown, S et al (2014). Progression in Keratoconus and the Effect of Corneal Cross-Linking on Progression. *Eye & Contact Lens* 40(6): 331-338
- O'Brart D et al (2014). Corneal collagen cross-linking: a review. *Journal of Optometry* 7:113-124.
- Chunyu T et al (2014). Corneal collagen cross-linking in keratoconus: a systematic review and meta-analysis. *Scientific reports* 4(5652) 1-8.
- Hashemi, H et al (2013). Topographic keratoconus is not rare in an Iranian population: The Tehran Eye Study. *Ophthalmic Epidemiology* 20(6): 385-91
- Jinabhai, A et al (2010) Pellucid corneal marginal degeneration: a review. *Contact Lens & Anterior Eye* 34: 56–63
- Jonas, J et al (2009) Prevalence and Associations of keratoconus in rural Maharashtra in Central India: The Central India Eye and Medical Study. *Am J Ophthalmol* 148:760-5.
- Rabinowitz, Y. (1998). Keratoconus. *Survey of Ophthalmology* 42(4):297-319
- Wolensack, G. et al (2003) Riboflavin/Ultraviolet-A-induced Collagen Crosslinking for the Treatment of Keratoconus. *Am J Ophthalmol* 135:620–627.